

## Efficiency of Kaolin and Activated Charcoal to Reduce the Toxicity of Low Level of Aflatoxin in Broilers

Hesham M. Teleb\*, Ali A Hegazy\*\* and Yehia A Hussein\*\*\*

Depts. \* Animal health, \*\* Pathology and \*\*\* Clinical studies.  
College of Vet.Med. & Anim.Res., King Faisal University,  
Al-Ahsa, Kingdom of Saudi Arabia

### Abstract :

Kaolin and activated charcoal were incorporated at 0.5% in diet to evaluate their ability to reduce the deleterious effects of 30 ppb total *aflatoxin* (AF) in broiler chicken. A total of 320 one-day old broiler chicks were divided into 4 equal treatment groups (control, AF contaminated, AF plus kaolin and AF plus activated charcoal). Chicken fed on diet containing 30 ppb AF for 45 days showed a significant decrease in live body weight and body weight gain with 20% mortality rate. Addition of kaolin and activated charcoal to the AF contaminated diet at 0.5% level reduced the mortality rate and improved body weight gain and efficiency of feed utilization. Histopathologically, the livers of birds of all groups except the control one showed focal hepatic necrosis, biliary epithelial hyperplasia, and granulomas. Pathological changes were highest among AF treated group. No AF residue could be detected in liver, breast, thigh and heart muscles in all birds.

### Introduction:

*Aflatoxin* (AF), a group of closely related extremely toxic chemicals, are produced by *Aspergillus flavus* and *Aspergillus parasiticus*. They can occur as natural contaminants of poultry feeds. The contamination of agricultural products with fungi that are able to produce mycotoxin is often unavoidable. Mycotoxins cause a wide variety of adverse clinical signs depending on the nature and concentration of mycotoxin, duration of exposure, animal species, and age and nutritional and health status at the time of exposure to the contaminated feed. The exposure of poultry to these toxins can mean the difference between profit and loss in poultry industry (Kaya *et al.*, 1990; Lesson *et al.*, 1995). The world-wide problem of mycotoxicosis is reflected by the fact that over 60 countries have either legislation or proposed legislation for the control of mycotoxicosis in both human and animal feed (Vanegmond, 1995). There is no effective way of destroying mycotoxin

once is formed. Practical and effective methods to detoxify AF containing feedstuffs are in great demand. A variety of physical, chemical and biological approaches have been tried (Goldblatt and Dollear, 1979; Anderson, 1983; Smith, 1984; Philips *et al.*, 1988; Gazia *et al.*, 1991; Park, 1993 and Santurio *et al.*, 1999). Another approach to the problem has been to use non-nutritive and inert adsorbents in the diet to bind AF and reduce their absorption from gastrointestinal tract. These compounds must not be absorbed from gastrointestinal tract and must have the ability to bind physically with the chemical substances and precludes their absorption. The major advantages of these adsorbents include expense, safety, and easy administration through addition to the animal feed (Ledoux *et al.*, 1999). Zeolites (hydrated sodium calcium aluminosilicate (Kubena *et al.*, 1993 & 1998; Kececi *et al.*, 1998; and Ledoux *et al.*, 1999), activated charcoal (Dalvi and Ademoyero, 1984; Dalvi and McGowan, 1984; Kubena *et al.*, 1993 & 1998) and clinoptilolite (Oguz *et al.*, 2000) have been used for this purpose. Food and Drugs Administration (FDA) of the United States of America estimated 20 ppb as tentative maximal allowance tolerance of AF in broiler feed. The objectives of this study were to evaluate the efficiency of two binding agents (kaolin and activated charcoal) for protection against low-level Aflatoxicosis, in broiler chicken. Growth performance, histopathological change, and AF residue in the edible meat were utilized as evaluatory parameters.

## Materials and Methods

### Chicken and diets

Three hundred and twenty of one-day old broiler chicks (Hubbard) of both sex obtained from a commercial hatchery were used in this study. Chicks were individually weighed and divided randomly into four equal designated groups 1, 2, 3 and 4. Chicks were allowed access to feed and water *ad libitum*. Basal diet was formulated according to the National Research Council (NRC, 1994) requirement. The basal diet was tested for possible residual AF before feeding (Samuel, 1978). The experiment lasted 45 days.

### Aflatoxin preparation:

*Aspergillus flavus* was grown on corn meal as described by Harvey *et al.* (1989), and Kubena *et al.* (1990 & 1993). The contaminated AF corn was



analyzed for AF content using Thin Layer Chromatography (TLC) Samuel (1978). The contaminated corn was incorporated into diets every three days to achieve the desirable concentration of 30  $\mu$ g total AF/ kg of feed.

### **Experimental design:**

The experimental chicks were allocated into four groups of 80 chicks each. Each group was fed as follows: group 1, control basal diet; group 2, basal diet plus 30  $\mu$ g AF /kg; group 3, basal diet plus 30  $\mu$ g AF / kg plus 0.5% kaolin; group 4, basal diet plus 30  $\mu$ g AF / kg plus 0.5% activated charcoal (Table 1).

Birds were observed daily for mortality and adverse clinical signs throughout the experimental period. Feed consumption and body-weight were determined weekly. On days, 20, 30, and 45 (end of experiment) 5 chicken of each group were weighed and slaughtered. A detailed necropsy was performed. The liver, spleen, bursa of fabricius and thymus were weighed. Specimens of these organs were collected in 10% neutral buffer formalin and processed for histopathology by standard paraffin method. Tissue sections of 3.5  $\mu$ m thickness were cut and stained with haematoxylin and eosin. Samples of breast and thigh muscles, heart, and liver were analysed for AF residue using TLC technique according to the method of Stzelecki (1978).

### **Statistical analysis:**

The data for live body-weight, body-weight gain, feed gain and relative weight of internal organs were expressed as mean + pooled standard error of means. Statements of statistical significance were based on  $P \leq 0.05$ , using analysis of variance.

### **Results:**

There was a significant ( $P \leq 0.05$ ) reduction in body-weight gain (7%) in chicken fed diet contaminated with 30 ppb AF compared to the control group. The decrease in body weight gain caused by AF was diminished by addition of 0.5 % of either kaolin or activated charcoal (Table, 1). Body weight gain was not significantly influenced when both kaolin and activated charcoal were added to the diet contaminated with AF compared with control basal diet group. The efficiency of feed utilization (kg feed / kg body

**Table ( 1 )**

Effect of Koalin ( K ) and activated charcoal ( C ) on body weight gain ,  
Efficiency of feed utilization and mortality (%) of broilers fed 30 ppb AF for 45 days

Basal diet	AF 30ppb	K 0.50%	C 0.50%	Initial body weight (g)	Final body weight (g)	Body weight gain (g)	Change from control (%)	Feed efficiency kg/kg	Mortality %
Group 1	-	-	-	41.2 <sup>a</sup> ± 1.0	1450.8 <sup>a</sup> ± 95.0	1408.8 <sup>a</sup> ± 90.3	0	2.4 <sup>a</sup> ± 0.15	2
Group 2	+	-	-	40.9 <sup>a</sup> ± 1.2	1350.0 <sup>b</sup> ± 210.0	1309.6 <sup>b</sup> ± 151.6	-7.04	3.2 <sup>b</sup> ± 0.9	20
Group 3	+	+	-	39.9 <sup>a</sup> ± 1.1	1410.0 <sup>a</sup> ± 105.0	1370.1 <sup>a</sup> ± 101.0	-2.74	2.7 <sup>a</sup> ± 0.18	15
Group 4	+	-	+	40.1 <sup>a</sup> ± 0.9	1440.0 <sup>a</sup> ± 110.0	1399.9 <sup>a</sup> ± 99.2	-0.63	2.8 <sup>a</sup> ± 0.11	12

Values represent the (  $\bar{X}$  = SEM ) of 15 broilers per treatment.

a,b : means within a column with no common superscript letters are significantly different (  $P \leq 0.05$  )



weight gain) was lower ( $P \leq 0.05$ ) in group 2 chicks fed AF contaminated diet than the control group. Both groups 2 and 3 chicks fed AF contaminated diet plus either kaolin or activated charcoal showed similar values. Regarding mortality rate, chicken fed AF contaminated diet had the highest mortality rate of 20% followed by chicken fed AF contaminated diet and treated by kaolin or activated charcoal (Table, 1). No relevant macroscopic post mortem changes were observed at necropsy.

Data presented in Table (2), show the effect of dietary treatments on relative weight of liver, heart, spleen and bursa of fabricous. Feeding a diet contaminated by 30 ppb AF resulted in a significant increase in relative weight of liver at 20 days of age compared to other dietary treatments. There was non-significant increase in liver weight throughout the rest of the experimental period. A significant increase was recorded in weight of bursa of fabricous at 35 days of age, in group 3 chicks fed AF contaminated diet plus kaolin. No significant difference was observed in relative weight of heart or spleen in all groups throughout the experimental period.

No AF residues were detected in specimens of breast and thigh muscles, heart, and spleen from birds slaughtered at 20, 35 and 45 days of age.

It is clear that the type of the lesions were similar in all groups, where as the incidence and severity of lesions were comparatively less common in groups treated with kaolin or activated charcoal. The liver of all chicken consuming diet contaminated by 30 ppb AF showed diffused areas of hepatic vacuolar degeneration. The hepatocytes appeared swollen, vaculated with pyknotic nuclei. Bile duct proliferation occasionally associated with fibrosis, granuloma and periportal aggregation of mononuclear cells and heterophils and kupffer cell proliferation was observed in the liver (Fig.1). Hyperplasia of epithelial lining of gall bladder was detected in two cases. Lymphoid depletion of bursa of fabricous was also seen. In group 3, chicks fed diet containing 30 ppb AF and 0.5% kaolin, there were focal areas of hydropic degeneration (Fig. 2). Fatty infiltration was detected in two birds. Hyperplasia of bile ducts, granulomas, focal areas of portal and parenchymal aggregation of mononuclear cells (Fig. 3) and heterophils in association with hepatic necrosis (Fig. 4) and kupffer cell hyperplasia were observed in individual cases at 35 and 45 days of age. The hepatic lesions of chick fed diet containing 30 ppb AF and 0.5% activated

Table ( 2 )

Effect of kaolin ( 0.5% ) and activated charcoal ( 0.5% ) on relative weight ( g ) of internal organs of chicken fed diets containing 30 ppb aflatoxin for 45 day

	AF 30 pp b	K 0.5%	C 0.5%	liver			heart			Spleen			bursa		
				20 d	35 d	45 d	20 d	35 d	45 d	20 d	35 d	45 d	20 d	35 d	45 d
Group 1	-	-	-	3.23 <sup>a</sup> ± 0.07	2.46 <sup>a</sup> ± 0.1	2.3 <sup>a</sup> ± 0.2	0.15 ± 0.03	0.41 <sup>a</sup> ± 0.02	0.4 <sup>a</sup> ± 0.03	0.19 <sup>a</sup> ± 0.003	0.4 ± 0.003	0.09 <sup>a</sup> ± 0.002	0.13 <sup>a</sup> ± 0.04	0.07 <sup>a</sup> ± 0.01	0.05 <sup>a</sup> ± 0.02
Group 2	+	-	-	3.89 <sup>b</sup> ± 0	2.99 <sup>a</sup> ± 0.41	2.69 <sup>a</sup> ± 0.52	0.58 ± 0.06	0.48 <sup>a</sup> ± 0.06	0.4 <sup>a</sup> ± 0.04	0.14 <sup>a</sup> ± 0.003	0.15 ± 0.004	0.07 <sup>a</sup> ± 0.006	0.17 <sup>a</sup> ± 0.06	0.07 <sup>a</sup> ± 0.04	0.06 <sup>a</sup> ± 0.02
Group 3	+	+	-	3.14 <sup>a</sup> ± 0.3	2.69 <sup>a</sup> ± 0.53	2.45 <sup>a</sup> ± 0.4	0.45 ± 0.04	0.44 <sup>a</sup> ± 0.03	0.37 <sup>a</sup> ± 0.05	0.2 <sup>a</sup> ± 0.003	0.34 ± 0.005	0.08 <sup>a</sup> ± 0.003	0.15 <sup>a</sup> ± 0.05	1.1 <sup>b</sup> ± 0.1	0.05 <sup>a</sup> ± 0.01
Group 4	+	-	+	2.99 <sup>a</sup> ± 0.12	2.51 <sup>a</sup> ± 0.33	2.48 <sup>a</sup> ± 0.46	0.54 ± 0.03	0.43 <sup>a</sup> ± 0.05	0.43 <sup>a</sup> ± 0.06	0.11 <sup>a</sup> ± 0.002	0.18 ± 0.007	0.08 <sup>a</sup> ± 0.004	0.14 <sup>a</sup> ± 0.07	0.05 <sup>a</sup> ± 0.02	0.04 <sup>a</sup> ± 0.004

a,b : means within a column with no common superscript letters are significantly different (  $P \leq 0.05$  )

charcoal showed fibrinous perihepatitis (2 cases) moderate to diffuse areas of hepatic vacular degeneration, hyperplasia of bile ducts occassionally associated with fibrosis. Portal mononuclear and hetrophilic cell aggregation were also seen. These changes were observed after 35 days of treatement (Table 3)

**Table ( 3 )**  
Effect of addition of koalin and activated charcoal  
on histopathological lesions

	AF		Koalin		Charcol	
	35d.	45d.	35d	45d	35d	45d
Fibrinous Perihepatitis					2	
Fatty changes			2			
Hepatic degeneration						
a. Focal area		1	1	2		2
b. Diffuse	3		1	1	3	
Billiary hyperplasia	3	1	2	1	2	
Fibrosis	2	1		1	2	1
Hepatic necrosis						
a. Focal	3	1	3	3	3	1
b. Diffuse		1	1			
Focal infiltration with Mononuclus cells	3	2	2	1	2	2
Hepatic infiltration						
Parenchymal Granuloma	3	1	3		1	
Gall blader hyperplasia	2		1			
Hepatic heamorrhage And thromb			1			
Hepatic dissociation And cellular atrophy			2			
Kupffer cell Proliferation		1				
Congestion		1				
Bursa lymphoid Depletion		1				
Heart focal area of necrosis		1				



**Discussion:**

In this study, experimental aflatoxicosis was induced in broiler chickens by feeding 30 ppb AF/kg diet from one day old until 45 days old. In intoxicated broilers a significant decrease in body weight gain and efficiency of feed utilization as well as high mortality was observed. These results are in agreement with those of Bailey *et al.* (1998) and Kubena *et al.* (1998). The adverse effect of AF can be shown to inhibition of metabolizing capacity (Dalvi and Ademoyero, 1984), protein and nucleic acid synthesis (Smith and Hamilton, 1970) and suppress mitosis and DNA synthesis (Legator, 1966). These may explain the nucliobiotic changes, which were seen in the livers of AF, treated birds.

The present study shows that addition of either kaolin or activated charcoal to AF contaminated diet tends to improve the body weight gain and feed utilization. Similar effects were reported by Dalvi and Ademoyero (1984) and Dalvi and McGown (1984). In contrast to these results, Kubena *et al.* (1990) reported that the addition of activated charcoal to the diet did not appear to have protective properties against the effect of AFB<sub>1</sub>. The level of AF used in this work was very low 30  $\mu$ g/kg compared to level of 10 ppm used by Delvi and Ademoyero (1984). Activated charcoal is non-adsorbable carrier that adsorbe to toxic molecules, thereby eliminating their absotrption from the intestinal tract. Kubena *et al.* (1990) reported that addition of activated charcoal to AF contaminated diet increases mortality rate in chicken compared to those fed AF contaminated diet only, so activated charcoal may have actually exacerbated the toxic effect. This has not been observed in this study, as group 4 chicks fed charcoal plus AF contaminated diet had less mortality than either groups 1, 2 and 3 which were either fed AF contaminated diet alone or with kaolin. The histopathological lesions were also less severe in groups 4 and 3 than AF fed chicks (group 2).

The present data shows that the relative weight of liver was significantly increased for chicks consuming AF than those fed AF with addition of either kaolin or activated charcoal. Huff *et al.* (1986) and Kubena *et al.* (1990) reported similar effect on relative weight of liver. These increases in relative weight of livers may be due to liver damage, as this organ is considered the principle target organ for aflatoxicosis (Dalvi and Ademoyero, 1984). The principle lesions observed in this study occurred in

the liver. It is classified as toxic hepatitis where hepatic cells vacuolization, fatty changes, biliary hyperplasia, portal fibrosis, and granuloma were the predominant changes. These agreed with data reported for chicken (Kubena *et al.*, 1990; Espada *et al.*, 1992). Aflatoxin B induced an accumulation of lipids in the liver and can be explained according to Huff *et al.* (1985) by an increase in the concentration of liver lipids. This increase may be due to general inhibition of lipid transport (Tung, *et al.*, 1972) or from interference of lipogenesis (Donaldson *et al.*, 1972). Fatty changes in the liver of two birds treated with kaolin was observed after 35 days of treatment and disappeared at 45 days. Perihepatitis was observed in two cases of group 3 chicks treated by kaolin after 35 days of treatment is of doubtful significance in relation to AF treatment as well as to kaolin. It was absent at 45 days of treatment with kaolin or diet without kaolin. There is no available data concerning the effect of AF with kaolin or activated charcoal on relative weight of heart and spleen. However, as can be seen from table 2, there was a moderate increase in the relative weight of these organs in AF fed chicks (groups 2, 3, and 4). The increase in the relative weight of spleen might be a compensatory mechanism for the drop in weight (and activity) of the bursa of Fabricius. The relative weight of bursa of Fabricius was fluctuating throughout the experimental period, and was much lower (0.04-0.17 g) than the weight (0.55-0.63 g) reported by Kubena *et al.* (1990), who observed birds up to day 28 of age. A decrease in relative weight of bursa of Fabricius in chicken fed AF contaminated diet or AF contaminated diet plus charcoal was also reported Kubena *et al.* (1993) and could be attributed to an immunosuppressive effect of AF.

There were no detectable AF residues in pieces of breast and thigh muscle, heart, and spleen from birds slaughtered at all stages. These results are parallel to those recorded by others. White Leghorn laying hens fed a diet containing 2.7 mg/kg for seven weeks had no AF residues in the eggs muscle, or liver (Kratzer *et al.*, 1969). Laying hens were exposed to AF by two methods: the first involved graduated dietary levels of zero, two, four, and eight mg/kg; the second, oral administration of 120, 240 and 480  $\mu$ g/kg of body weight. No AF residues were detected (Sims *et al.*, 1970). Likewise, Van Zytveld *et al.* (1970) exposed White Rock chicks to daily dosages ranging from 0.4 to 1.7 g of mixed AF/kg for six weeks. The authors failed to detect AF residues at slaughter. Similar results were



recorded in other animal species, such as swine and steers Booth (1969). The analytical methods used have a minimum detection limit in the order of three to five  $\mu\text{g AF/kg}$  of sample.

The bursa of fabricous showed lymphoid depletion in group 2 chicks treated with AF alone. Similar results were obtained by Kubena *et al.* (1990), Kececia *et al.* (1995) and Kiram *et al.* (1998). It is apparent that the absorption therapy reduced the deleterious effect of AF on lymphoid tissue as no change could be detected in the bursae of birds of kaolin or charcoal treated groups. The number of affected chicks and the severity of lesions in the liver were reduced after addition of kaolin and activated charcoal; thus it can be concluded that both adsorbant may have a noticeable effect in reducing AF toxicity in the liver. Further work should be carried out using different AF concentrations and kaolin or charcoal regimens in order to make use of this observation.



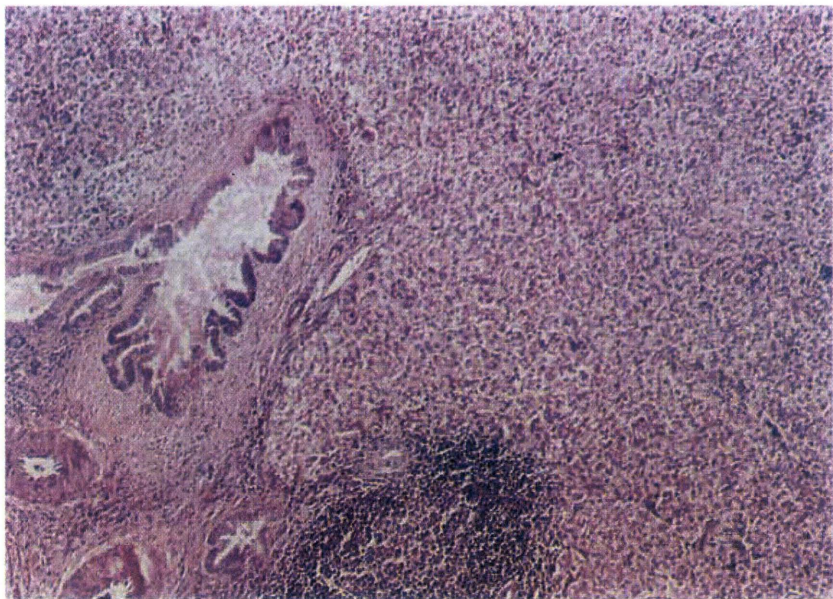


Fig. 1: Bile duct proliferation associated with fibrosis and granuloma in the liver of chicken fed 30 ppb AF for 45 days. (H&E. X200).

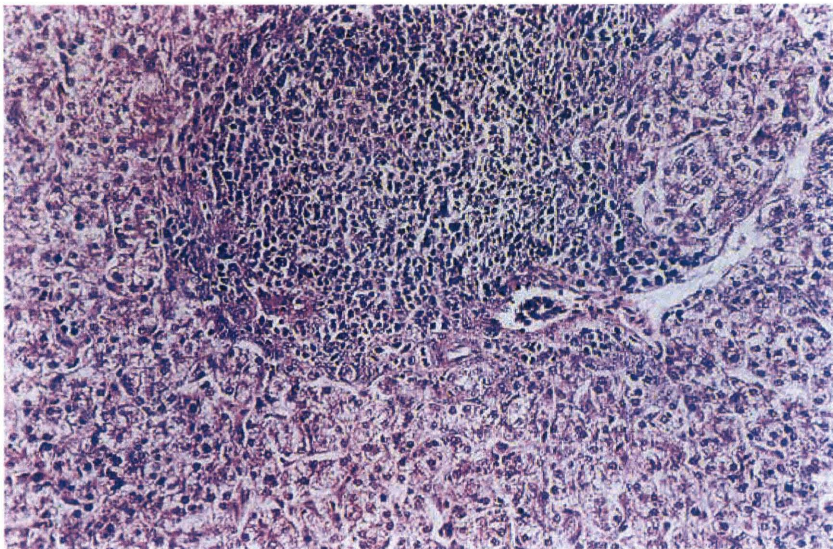


Fig. 2: Hepatic cell vacuolation and granulomas in chicken fed 30 ppb AF contaminated diet for 45 days. ( H & E. X 200)



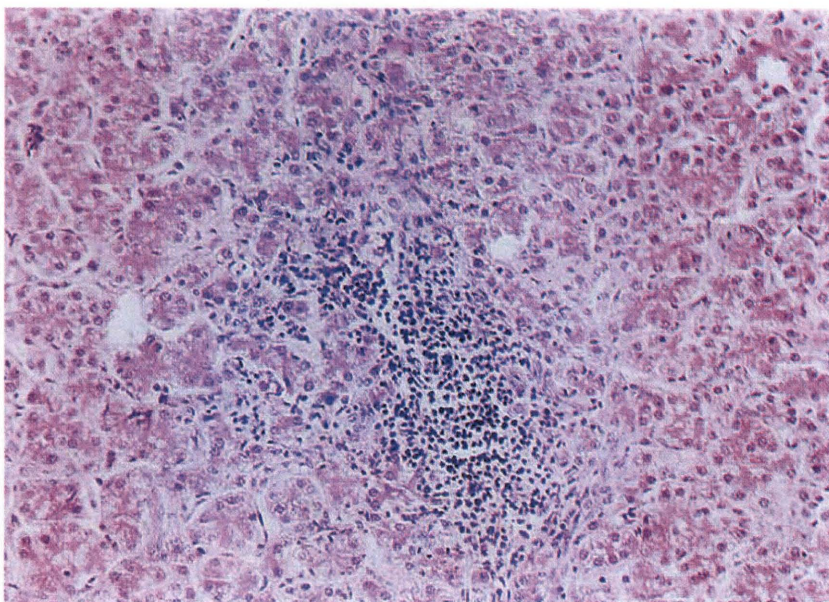


Fig. 3 : Parenchymal and mononuclear cell aggregation in liver of chicken fed 30 ppb AF contaminated diet. ( H & E. X 200)

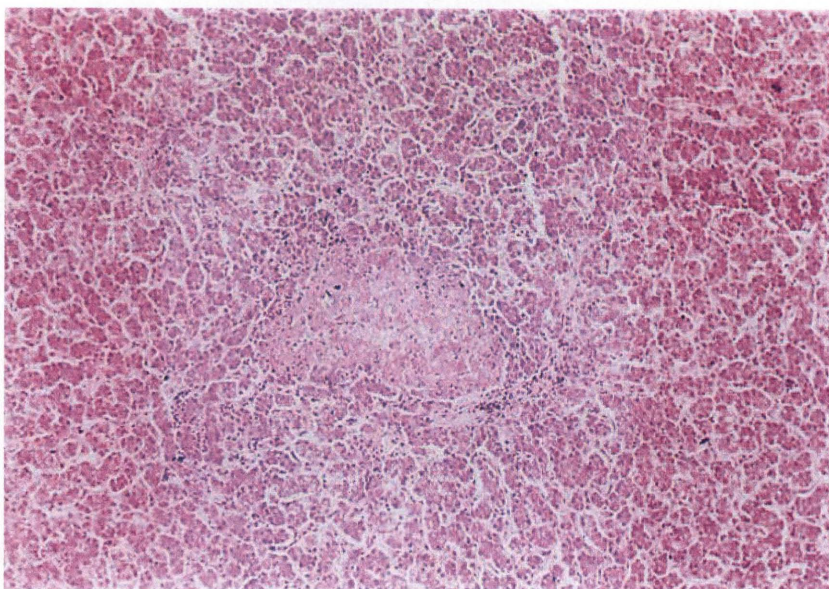


Fig. 4 : Focal area of hepatic necrosis in chicken fed 30 ppb AF for 45 days. (H & E. X 100)

## References:

1. Andrsn, R.A. (1983): Detoxification of aflatoxin contaminated corn. Page 87-90 in: Aflatoxin and *Aspergillus flavus* in corn. U. Dienex, R. Asquith, and J. Dickens, ed. Sonthern Coop. Ser., Bull, 279. Auburn University, Auburn, AL.
2. Bailey, R.H., Kubena, L.F., Harvey, R.B., Buckley, S.A. and Rollinghoira, G.E. (1998): Efficiency of various inorganic sorbeuls to reduce the toxicity of aflatoxin and T-2 toxin in broiler chicken. *Poultry Science* , 77, 1623-1630.
3. Booth, A.N. (1969): Review of the biological effects of aflatoxins on swine, cattle and poultry. *J. Am. Oil. Chemists Soc.* , 46, Abstr. 154.
4. Dalvi, R.R. and Mc Gowan (1984): Experimental induction of chronic aflatoxicosis in chicken by purified aflatoxin B and its reversal by activated charcoal , phenobarbital and reduced glutathine. *Poultry Sci.* , 63: 485-491.
5. Dalvi, R.R. and Ademoyero, A.A. (1984): Toxic effects of aflatoxin B in chicken given feed contaminated with *Aspergillus flavus* and reduction of the toxicity by activated charcoal and some chemical agents. *Avian Dis.* 28: 61-69.
6. Donaldson, W.E.; Tung, H.T. and Hamilton, P.B.(1972): Depression of fatty acid synthesis in chick liver (*Gallus domesticus*) by aflatoxin. *Compendium of biochemical physiology* 41 B ,843-847
7. Espada,Y.; Domingo,M.; Gomez,J. and Calvo,M.A. (1992): Pathological lesions following an experimental intoxication with aflatoxin B1 in broiler chickens. *Research in Vet. Sci.* 53, 275-279.
8. Gazia,N; Abd-Ellah,A.M. and Sayed,A.N. (1991): Chemical treatment of mycotoxin contaminated ration and possibility of its safety use of chicks. *Assiut Vet. Med. J.* 25(4a): 61-68.
9. Goldblatt, L.A. and Dollear, F.G. (1979): Modifying mycotoxin contamination in feeds- use of mold inhibitors, ammoniation roasting. In : *Interactions of Mycotoxins in AnimalProduction*. Natl. Acad. Sc., Washington, Dc.
10. Harvey,R.B., L.F. Kubena, T.D.Phillips ,W.E.Huff, and D.E.Corrier (1989): Prevention of Aflatoxicosis by addition of hydrated sodium calcium aluminosilicate to the diets of growing barrows. *Am.J.Vet.Res.* 50: 416-420.
11. Huff, W.E., Kubena, L.F., Harvey, R.B., Corrier, D. and Hollenhauer, H.H. (1986): Progression of aflatoxicosis in broiler chickens. *Poultry Sci.* , 65: 1891-1899.



12. Kaya,S. , Yavuz, H. and Akar, F. (1990): Mycotoxin residue in some oily seed meals. *A.U. Veteriner Fakultesi Dergisi.*, 37, 173-180.
13. Kececi,T., Oguz,H., Kurtoglu, V. and Demet,O. (1998): Effects of polyvinylpyrrolidone synthetic zeolite and bentonite on serum biochemical and haematological characters of broiler chicken during aflatoxicosis. *British Poultry Science* , 39, 452-458.
14. Kiram, M.M.; Demet, O. ; Ortatatli, M. and Oguz, H.(1998): The preventive effect of polyvinylpyrrolidone on aflatoxicosis in broilers. *Avian Pathology*, 27, 250- 255.
15. Kratzer,F.H.; Bandy,D.; Wiley,M. and Booth,A.N. (1969): Aflatoxin in poultry. *Proc. Soc. Expt. Biol. Med.*, 131, 1281.
16. Kubena,L.F.; Harvey,R.B.; Huff, W.E. and Corrier, D.E. (1990): Efficacy of hydrated sodium calcium aluminosilicate to reduce the toxicity of aflatoxin and T-2 toxin. *Poultry Science*. 69, 1078- 1086.
17. Kubena,L.F.; Harvey,R.B.; Philips,T.D.; Corrier,D.E. and Huff,W.E. (1993): Diminution of aflatoxicosis in growing chickens by the dietary addition of hydrated sodium calcium aluminosilicate. *Poultry Science*, 69, 727-735.
18. Kubena,L.F.; Harvey,B.R.; Bailey,R.H.; Buckley,S.A. and Rotlinghous (1998): Effects of hydrated sodium calcium aluminosilicate (T-Bind) on mycotoxicosis in young broiler chickens . *Poultry Science.*, 77, 1502-150
19. Ledoux,D.R.; Rotlinghous,G.E.; Bermudez,A.J.; and Alanso-drbolt,M. (1999): Efficacy of hydrated sodium calcium aluminosilicate to ameliorate the toxic effect of aflatoxin in broiler chicks. *Poultry Science.*, 78, 204-210.
20. Legator,M. (1966): Biological effects of aflatoxin in cell culture. *Bacterial Rev.*, 30, 471- 477.
21. Lesson,S.; Diaz,G. and Summers,J.D. (1995): Aflatoxins . In: *Poultry Metabolic Disorders and mycotoxins*. Eds. S. Leeson;G. Diaz;J.D.Summers. Ontario, Canada University Books pp 248-279.
22. National Research Council. NRC (1994): *Nutrient Requirement of Poultry* (th rev.ed.National Academy Press. Washington, Dc.
23. Oguz,H.;Kececi,I; Birdane,Y.O.; Onder,F. and Kurtoglu,V. (2000): Effect of clinoptilolite on serum biochemical and haematological characters of broiler chicks during aflatoxicosis . *Research in Vet Science*, 69: 89-93.
24. Park,D.L. (1993): Perspectives of mycotoxin decontamination . *Procedures of Food Additives and Contaminants*. 10, 49-60.

25. Pasteiner, S. (1997): Coping with mycotoxin contaminated feedstuffs. *Feed International*, 12-18.
26. Philips,T.D.; Kubena,L.F.; Harvey,R.B.; Taylor,D.S. and Heidelbaugh,N.D. (1988): Hydrated sodium calcium aluminosilicate: a high affinity absorbent for aflatoxin. *Poultry Science*. 67: 243-247.
27. Ramos,A.J.; Finkgremmels, S.J. and Hernandez,E. (1996): prevention of toxic effect of mycotoxins by means of nonnutritive absorbent compounds. *J.Food Protection* 59: 631-641.
28. Robb,J. (1993): Poison mycotoxins. In *Practice*. Nov. Vol.15(6): 278-280.
29. Samuel,K.C. (1978): Aflatoxin levels in laboratory animal diet components. *Zbl.Vet.Med. B*, 25, 173-177.
30. Santurio, J.M.; Mallmann, C.A.; Rosa, A.P.; Appel, G.; Hear,A. ; Dage-Forde, S. and Bottcher, M. (1999): Effect of sodium bentonite on the performance and blood variables of broiler chickens intoxicated with aflatoxin. *British poultry Science* 40, 115-119.
31. Sims,W.M.; Kelley,D.C. and Sanford,P.E. (1970): A study of aflatoxicosis in laying hens. *Poultry Sci*. 49: 1082.
32. Smith,J.W. and Hamilton,P.B. (1970) : Aflatoxicosis in the broiler chicken. *Poultry Sci*. 49: 207-215.
33. Smith,T.K. (1984): Spent canola oil bleaching clays: potential for treatment of T-2 toxicosis in rats and short-term inoculation in diets for immature swine.*Can.J. Anim. Sci*. 64: 725-732.
34. Strzelecki,E. L. (1978): Aflatoxin determination in animal tissues. *Zbl. Vet. Med.B*, 25, 194-201.
35. Tung, H.T.; Donaldson, W.E. and Hamilton, P.B. (1972): Altered lipid transport during aflatoxicosis. *Toxicology and Applied Pharmacology* 22, 97-104. Thaxton,J.P.; Tung,H.T. and Hanilton,P.B.. (1974): Immunosuppression in chickens by aflatoxin. *Poultry Sci*. 53: 721-725.
36. Vanegmond,H.P. (1995): Mycotoxins regulations, quality , assurance and reference materials. *Food Additive and Contaminants*. 12: 321-330.
37. Van Zytveld,W.A.; Kelley,D.C. and Dennis,S.M. (1970): Aflatoxicosis: The presence of aflatoxins or their metabolites in livers and skeletal muscles of chickens. *Poultry Sci*. 49: 1350

## كفاءة الكوالين و الفحم النشط فى تقليل سمية معدل بسيط من الأفلاتوكسين فى علائق بدارى التسمين

هشام محمد طلب - على عبد السلام حجازى ❖❖ - يحيى أحمد حسين ❖❖❖

قسم صحة الحيوان ❖❖❖ قسم الأمراض ❖❖❖ قسم الدراسات الأكاديمية

كلية الطب البيطرى و الثروة الحيوانية - جامعة الملك فيصل

الاحساء ٢١٩٨٢ ص.ب. ١٧٥٧

### الملخص :

تم ادماج الكوالين و الفحم النشط كعوامل ضامة فى العليقة عند مستوى ٠,٥% و ذلك لتقييم قدرتهما على تقليل الأثر الضار ل ٣٠ جزء فى البليون من سموم الأفلاتوكسين الكلية فى علائق كتاكيت بدارى التسمين. فقد قسمت ٣٢٠ كتكوت بدارى تسمين عمر يوم واحد الى ٤ مجموعات متساوية وهى مجموعة ضابطه ومجموعه عليقتها ملوثة بالأفلاتوكسين و مجموعه عليقتها ملوثة بالأفلاتوكسين ومعه كوالين و مجموعه عليقتها ملوثة بالأفلاتوكسين و معها الفحم النشط. و أظهرت الكتاكيت التى تغذت على عليقة تحتوى على ٣٠ جزء فى البليون لمدة ٤٥ يوم متتالية نقص معنوى فى وزن الجسم الحى طوال فترة التجربة و ٢٠% وفيات. وأن اضافة الكوالين و الفحم النشط الى العليقه بمستوى ٠,٥% قلل من معدل الوفيات و حسنت فى زيادة وزن الجسم و كفاءة الاستفادة من العليقه.

كما وأظهر الفحص النسيجي المرضى أن أكباد الطيور فى كل المجموعات ما عدا المجموعه الضابطه بها تنخر بؤرى للكبد و تكثر نسيجي طلائى صفراوى وأورام حبيبية بنسب مئوية متفاوتة بينما كان أعلى معدل للحدوث يوجد فيما بين المجموعه التى تغذت على العليقه الملوثة بالأفلاتوكسين.

ولم يتم اكتشاف أى متبقيات للأفلاتوكسين فى الكبد و عضلات الصدر والفخذ و القلب فى جميع مجموعات التجربة.