

Retrospective Study of Hernias in Goats

Abdin-Bey, M.R and Ramadan, R.O

College of Veterinary Medicine & Animal Resource -King Faisal University
P.O.Box 1757 , Al-Hasa 31982

ABSTRACT:

A total of 59 hernias in goats were studied at the Veterinary Teaching Hospital (VTH), King Faisal University (KFU). They constituted umbilical (28); ventral abdominal (19), inguinal (6), scrotal (4), perineal (2). Diagnosis was based on the clinical and radiographic findings. Contrast radiographs helped to assess the nature of hernial content & the postoperative follow up. Surgical repair gave favourable results.

INTRODUCTION:

Hernias have several deleterious effects, such as lowering the productivity and reproductivity of the affected animals. Diagnosis of hernias, based on clinical findings, may be confusing in some instances (Keown 1988, Purohit et al. 1983).

Abdominal, inguinal and perineal hernias could entrap a foetus or foetuses in their hernial sacs leading to dystocia (Roberts 1956, Radhakrishnan *et al.*1993, Sobiraj 1994). Surgical intervention could prolong the usefulness of such affected animals.

Despite these facts, reports on hernias in goats are very rare (Gohar et al. 1985).

The purpose of this paper is to highlight the necessity of using contrast media in the diagnosis of hernias in goats and to provide information on the management of 59 cases of such hernias.

MATERIALS AND METHODS:

During the five years 1993 - 1998, owners brought 193 goats suffering from hernial swellings to the Veterinary Teaching Hospital of King Faisal University. 59 animals were subjected to a detailed study. Each animal was examined clinically then the type of the hernia as well as its content was assessed (*Table.1*).

Table (1) : Details of 59 hernias in goats

Type of hernia	Age		Sex		Content
	< 1 year	> 1 year	M	F	
					Omentum (13), Intestines (18), Abomasum (9), Rumen (6), Gravid uterus (1), Umbilical cord remnant (3)
a. Umbilical	16	12	8	20	
b. Ventral abdominal	5	14	5	14	Omentum and intestines (12), abomasum (3), Gravid uterus (2), Rumen (3).
c. Inguinal	1	5	-	6	Gravid uterus (4). Rumen, abomasum, intestines (2).
d. Scrotal	4	0	4	0	Intestines (4).
e. Perineal	0	2	1	1	Rectum, fat
Total	26	33	18	41	
Total of cases	59				

Clinical Signs

Umbilical Hernias

The swelling ranged from 5 -18 cm in diameter (*Fig.1*). The site was in the center of umbilical region or 5 cm cranial, caudal or to one side of the umbilicus. Most umbilical hernias were reducible and their size was noticed to increase with coughing. The rings ranged from 1-4 in number. A gravid uterus was found in the content of one hernia (*Fig.2*).

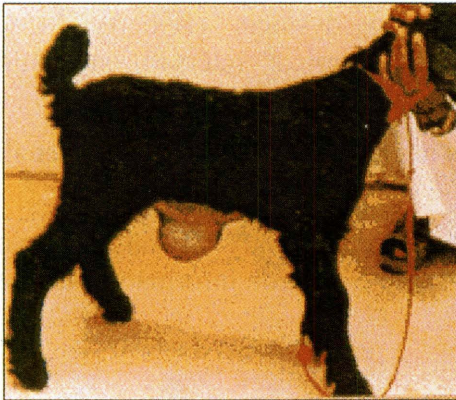


Fig. (1) : Umbilical hernia

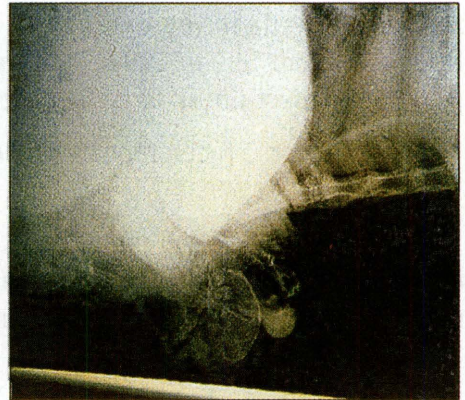
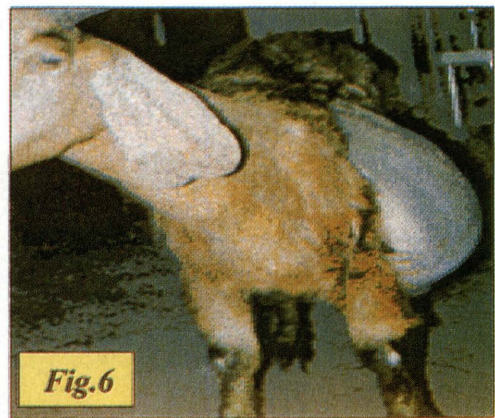
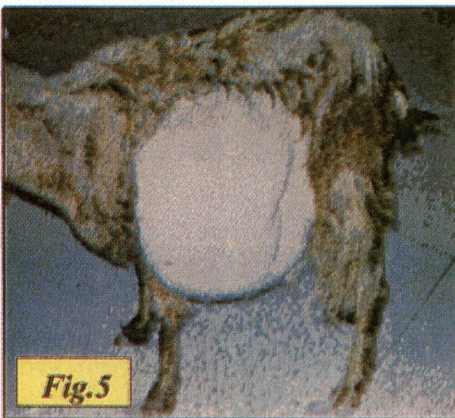
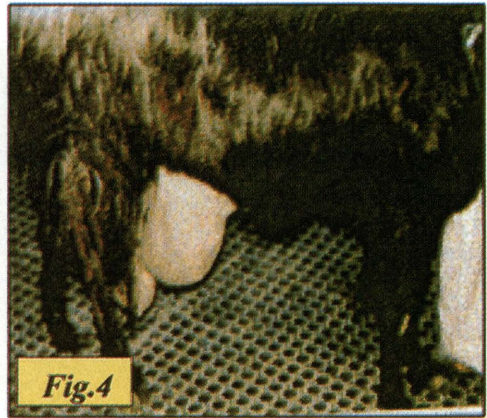



Fig. (2) : Lateral radiograph showing a gravid uterus in the hernial sac.

VENTRAL ABDOMINAL HERNIA:

The hernial swelling varied in location from iliac crest to the lateral side of the thoracic cavity (*Fig.3-5*). The size ranged from 15 40 cm in diameter. These swellings did not correspond, with the size of their rings. Thus the ring was found in a proximal location, while the content was sanguineous and occupied a diffuse latero-ventral location (*Fig.6*). Two goats had gravid uterus in the hernial swelling. Double hernial rings were not uncommon.



(3-6) : Ventral abdominal hernia Fig.

- (3) : The swelling was situated above stifle.
- (4) : Circumscribed swelling ventral to stifle.
- (5-6): Diffuse swelling which furrowed the subcutaneous tissue toward the latero-ventral thoracic region.

INGUINAL HERNIAS:

The size of the swelling ranged from 20 40 cm in diameter. The inguinal ring was ruptured, thus the swelling contained intestinal loops, rumen or gravid uterus (*Fig.7a-c and Fig.8*).

SCROTAL HERNIAS:

The swelling was unilateral in nature. Three animals had the hernia to the right side (*Fig.9*). The hernial content was loops of small intestines whereas the testicles were atrophied (*Fig.10*). Serous fluid was variable.




Fig. (7a-c) : Inguinal hernias in goats.

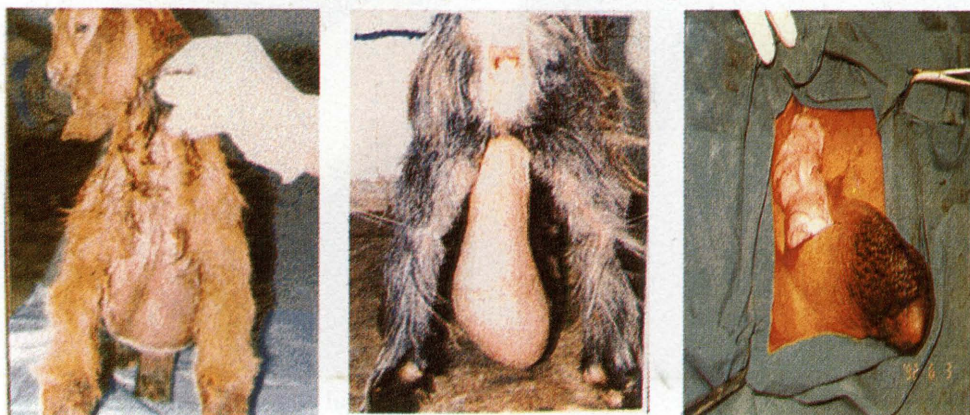

Fig. (8) : Inguinal hernia

Fig. (9) : Scrotal hernia

**Fig. (10) : Intestinal loops
in the Hernial sac**

PERINEAL HERNIAS:

The hernial swellings were located on the left ischio-rectal fossa in one animal and the right side of another goat. Examining fingers could enter the rectal diverticulum.

RADIOGRAPHIC EXAMINATION:

Plain radiographs were obtained from 16 animals in the routine lateral and ventro-dorsal projections. Six of these animals were subjected to contrast radiographic study using 100% barium sulphate suspensions (Micropaque Standard, Bartop 100, Nicholas Concept UK) at the dose of 15-20 ml/kg body weight. Immediate radiographs were taken, then serial pictures were obtained at intervals of 15 minutes over a one-hour period as well as after 24 hours, 48 hours and 72 hours. Postoperative radiographs were also taken (*Fig.11-13*).

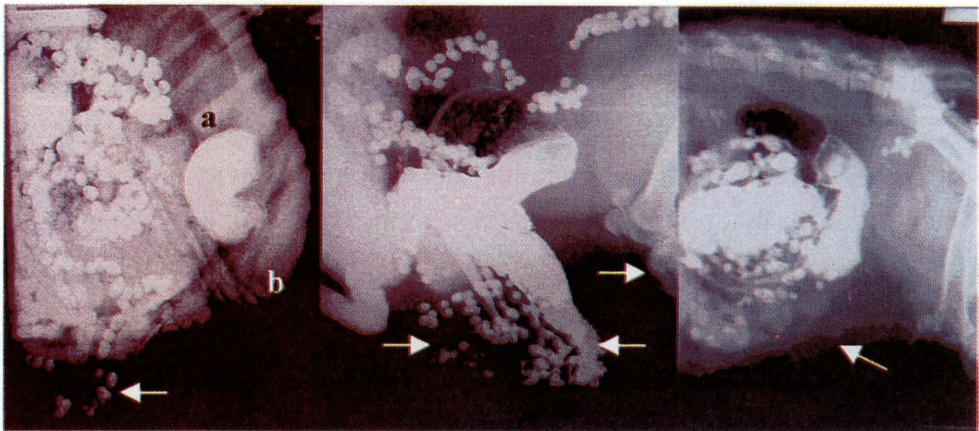


Fig. (11)

Fig. (12)

Fig. (13)

Lateral contrast radiographs showing loops of intestine;

Fig. (11) : in the hernial sac (arrow), **a:** Omasum **b:** Reticulum,

Fig. (12) : beyond the level of the stifle joint (arrow),

Fig. (13) : same animal as in Fig.12 post operative.

ANAESTHESIA AND OPERATIVE PROCEDURES:

Food was withheld 24 hrs preoperatively, after that each animal was anaesthetized with Xylazine (Rompun 2%, Bayer) and Ketamine hydrochloride (Ketaset, Bristol Lab. Syracuse, N.Y) given intravenously at a dose of 0.1 mg/kg bwt. and 5 mg/kg bwt. respectively. Further increment of the same anaesthetic mixture was given within a period of 10-20 minutes in order to maintain the anaesthesia if needed.

SURGERY:

Umbilical Hernia; Ventral Abdominal Hernias:

An elliptical incision was made around the neck of the hernial swelling, avoiding the subcutaneous abdominal veins from either side. Alternatively the initial incision was made on the fundus of the hernias, thus avoiding the engorged veins. In umbilical hernias in the male, the incision was either cranial or on one side of the preputial orifice (*Fig.14*). The skin was then carefully dissected, the ring was identified and any redundant tissue was excised. The content was returned into the abdominal cavity. The ring was coaptated with mattress or myo-mattress suture pattern using Dexon No. 5 metric or braided polyester sutures 5 metric (Ethibond, Ethicon LTD.). Skin and subcutaneous tissue closure was routine (*Fig.15-16*).

Scrotal Hernia

A longitudinal skin incision was made at the base of the scrotum. The content was reduced, the spermatic cord was twisted and a ligature was tied at its neck. The testicle was then removed. The inguinal ring as well as the dead space was then closed with Dexon, No.5 metric. The skin was sutured with nonabsorbable material, which was removed in 7-10 days (*Fig.17*).

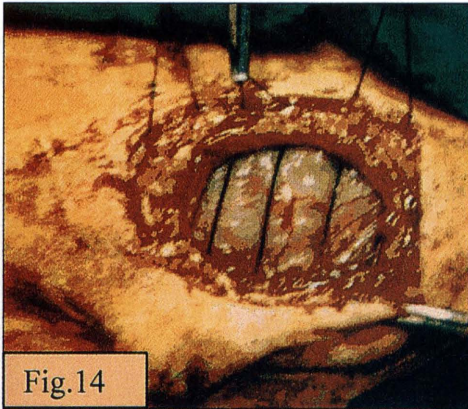


Fig.14

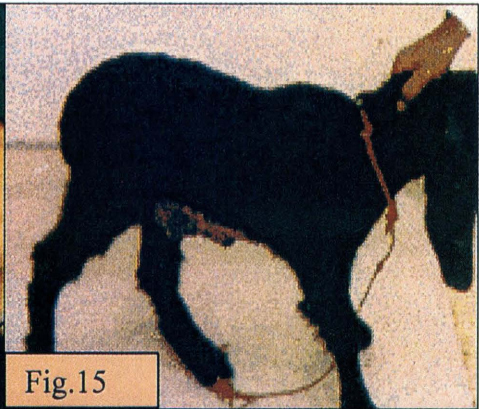


Fig.15

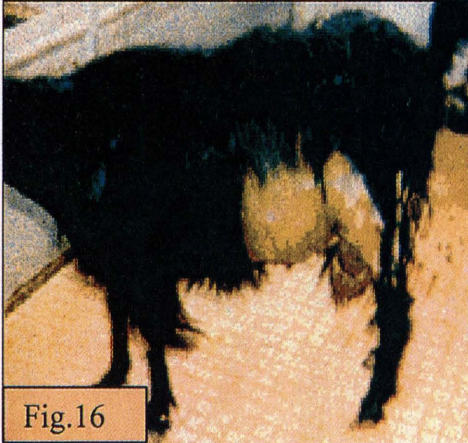

Fig.16

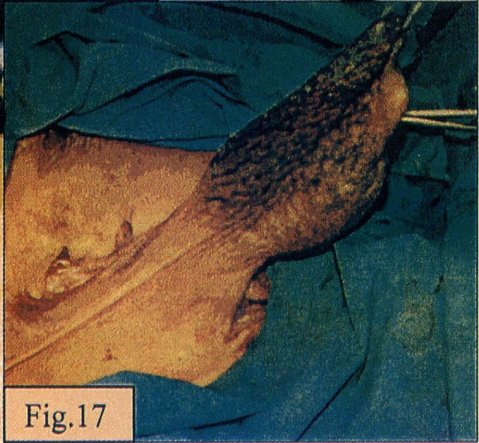


Fig.17

Fig. 14, Incision lateral to preputial orifice

Fig. 15, Umbilical hernia of Fig. 1 after operation

Fig. 16, Abdominal hernia of Fig. 3 after operation

Fig. 17, Scrotal hernia

INGUINAL HERNIA:

A skin incision was made over the inguinal swelling; the contents were identified and returned into the abdominal cavity. The ring was sutured with interrupted mattress or figures-of-8-suture pattern using No.5 metric polyester material. Four animals were admitted at the late stage of gestation and cesarean sections were performed at the time of herniorrhaphy (*Fig.18 a-f*). Torsion of the gravid horn was observed in one out of 4 metroceles.

PERINEAL HERNIA:

Repair of perineal hernia was achieved by suturing the separation between the levator ani muscle and the external sphincter muscle of the anus with Dexon No 5 metric Hickman and Walker (1980).

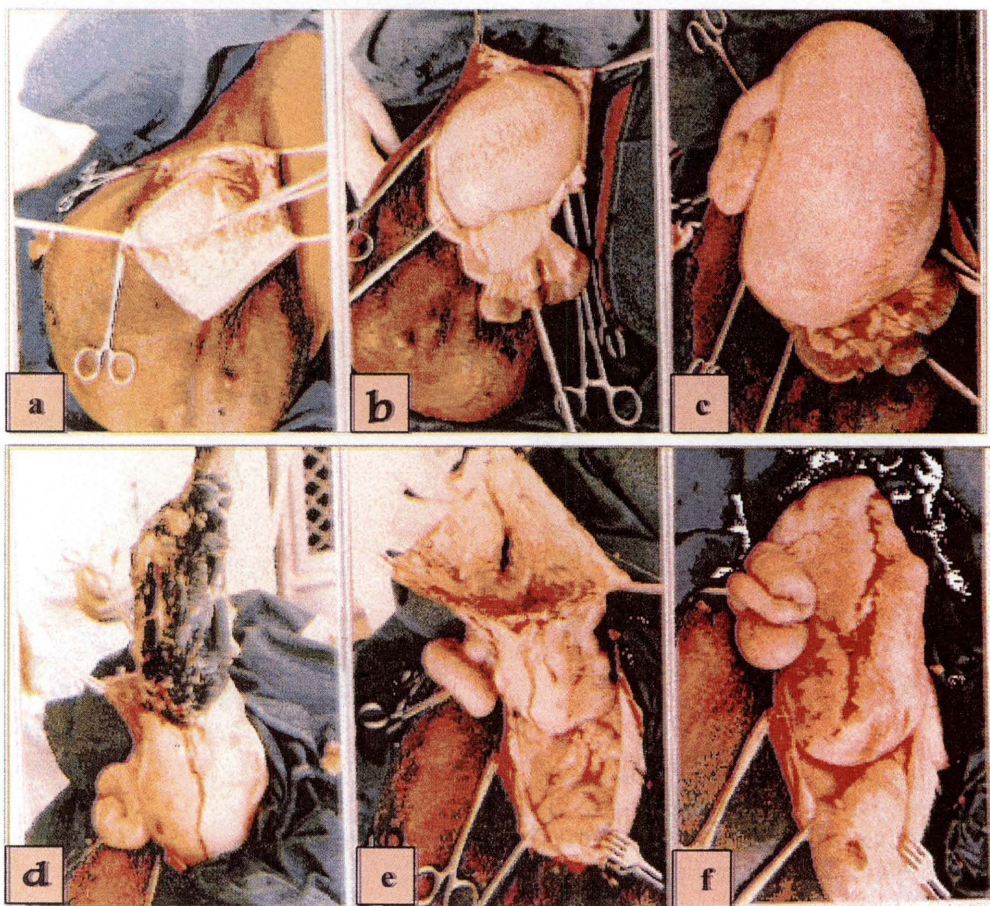


Fig. (18) (a-f), Gravid uterus was found in the hernial sac.

RESULTS:

Reference to Table.1 showed that umbilical, ventral abdominal, scrotal, inguinal and perineal hernias are common in Al Ahsa region. The content of the hernias was predominantly omentum followed by the intestines then abomasum , the rumen and the gravid uterus. Umbilical and scrotal hernias

were more frequent in young animals of less than one year in age, while ventral abdominal and inguinal hernias were observed more in adults. Adhesion between the internal hernial sac and hernial content was noted in the majority of the cases. The adhesion tended to increase with the chronicity of the lesion.

Radiographic studies using barium sulphate suspension was versatile in confirming the diagnosis of hernias. They showed clearly the nature of the content and helped greatly in assessing the post-operative position of the bowel. The contrast media outlined the intestines within one and a half hour and remained in the caecum and large intestines up to 72 hours.

The result of surgical interference was promising. Four goats (6.8%) were readmitted because of recurrence, one animal (1.7%) with local infection while another goat (1.7%) died within 24 hours.

DISCUSSION:

The present study showed that more females were affected than male animals (41/18). However this might be due to the fact that owners keep more female in the farm, culling male animals at an early age.

It is interesting that the majority of hernias appeared at the site of natural orifices such as the umbilical and inguinal canal of immature animals, thus suggesting their developmental status (Dennis and Leipold 1968). On the other hand abdominal hernias were found in adult goats, a matter which supports the hypothesis that abdominal hernias were mostly traumatic in nature (Gohar et al. 1987).

Upon delivery to us, seven animals had abscesses in the umbilical region and three had remnant of umbilical cord and another goat had a lax weak prepubic tendon. These lesions could be taken as predisposing factors in the aetiology of hernias (Frank 1964; Ramadan 1994).

The size of the hernial swelling was greater in ventral abdominal and inguinal hernias of the adult goat. This may be attributed to rupture of the peritoneum and escape of the content to the subcutaneous tissues (Youssef et al. 1994).

Our surgical intervention met with reasonable success. Although we had treated two instances of hernias: one inguinal and one abdominal, (the ring of which was about 40 cm long), we support the suggestion that the repair of large sized hernial ring could be better performed using prosthetic meshes (Youssef et al.1994; Shoukry et el. 1997). The repair of large hernial defect without prosthetic meshes might result in failure due to excessive tension on the suture line in addition to the presence of weakened tissue around the hernial ring.

We utilized contrast radiography in confirming our diagnosis and assessing post-operative follow up in six goats. We strongly advise this approach, particularly in conjunction with scrotal and inguinal hernias. In this situation post-operative reherniation or seroma formation may be anticipated. Therefore contrast radiography could give an immediate differential diagnosis.

A survey of the available literature showed that contrast radiography has been used for the diagnosis of diaphragmatic hernias in buffaloes and cattle (Krisnamurthy et al. 1983; Kumar et al. 1980) and in sheep (Ramadan and Abdin-Bey 1996) but no report was cited in the goat.

Acknowledgements

Thanks are due to our colleagues in the Veterinary Teaching Hospital, especially Dr. A. Wahab Al Hulaibi and El Sir M. Abdalla and Dr. Hussain A. Abdullah for there valuable help.

REFERENCES:

1. Dennis,S.M and Leipold,H.W. (1968). Congenital hernias in sheep. J. Amer. Vet. Med. Ass. 152: 999-1003.
2. Frank, E.R. (1964). Veterinary Surgery, 7th ed., Burgess Publishing Co., Minneapolis, Minn., USA.
3. Gohar,H.M., Ramadan,R.O and Mugal,H. (1985). Abdominal hernia in sheep and goats. Proc. Saudi Biol. Soc. 8:289-297.
4. Gohar,H.M., Ramadan,R.O and Mugal,H. (1987). Umbilical and abdominal hernias in ruminants. J.Egypt.Vet.Med.Ass. 47:563-575.
5. Hickman,J and Walker,R (1980). Perineal rupture. *In* Atlas of Veterinary Surgery. 2nd Ed. John Wright & Sons LTD Bristol.
6. Keown,G.H (1988). Textbook of large animal surgery. Ed. F.W.Oehme Baltimore London.
7. Krishnamurthy,D., Nigam,J.M., Peshin,P.K., Sharma,S.N, Chawla,S.K and Singh,Jit (1983). Diagnosis and repair of multiple hernial rings in diaphragm of she buffaloes. India Vet.J., 60:480-484.
8. Kumar,R., Kohli,R.N., Prasad,B.,Singh,Jit and Sharma,S.N (1980). Radiographic diagnosis of diaphragmatic hernia in cattle. Vet.Med./S.A.C., 17:305-309.
9. Purohit,R.K., Choudhary,R.J. and Choudhary,D.S (1983). Surgical repair of ventral hernia in sheep. Indian Vet. J. 60:404-405.
10. Radhakrishnan,C., Balasubramanian,S and Thilagar,S. (1993). Repair of ventral metrocele (gravid) in a goat. Vet.Rec. 132:92
11. Ramadan,R.O (1994). Herniorrhapy: *In* Surgery and radiology of the dromedary camel. Ramadan,R.O., King Faisal University Al Ahsa., Saudi Arabia.
12. Ramadan,R.O., and Abdin-Bey, M.R (1996). An Atypical case of diaphragmatic hernia in a Najdi sheep. Pakistan Vet.J. 16:202-203
13. Roberts,S.J(1956). *In* Veterinary Obstetrics & Genital disease (Theriogenology). Woodshoock, Vermont, 05091, Michigan, USA.
14. Shoukry,M., El-Keiey,M., Hamouda,M and Gadallah,Y (1997). Commercial polyester fabric repair of abdominal hernias and defects. Vet.Rec. 140:606-660
15. Sobiraj,A. (1994). Birth difficulties in sheep and goats, evaluation of patient outcome from seven lambing periods in an obstetrical clinic. DTW, Dtsch-Tierarztl-Wochenschr., 101:471-476.
16. Youssef,H.A., Saleem,S.M., Saleh,A.S., Ali,S.M and Ali,M.A (1994). Zur Therapie einiger seltener Hernien. Der Praktische Tierarzt, 1:31-33.

دراسة استعادة لحالات الفتق في الماعز

محمد رصين عابدين بك - رمضان عمر رمضان

كلية الطب البيطري والثروة الحيوانية - جامعة الملك فيصل - الأحساء

الملخص :

تم خلال الخمس سنوات السابقة دراسة ٥٩ حالة من الماعز التي أحضرت إلى المستشفى البيطري التعليمي التابع لجامعة الملك فيصل بالأحساء من جراء إصابتها بالفتق. وبعد إجراء الفحص الإكلينيكي والإشعاعي صنفت هذه الحالات بالفتق السري (٢٨)، والبطني (١٩)، الأربي (٦)، والخصوي (٤)، والعجاني (٢). تم استخدام التصوير الإشعاعي مدعماً بالصور الإشعاعية الظليلة بعد تجريح الحيوان سلفاً الباريوم وبطريقة لم يسبق نشرها في مثل هذه الدراسة. أوضحت هذه الطريقة أهميتها في تحديد مكونات الفتق ومن ثم تتبع سير العملية الجراحية. هذا وقد أوضح استبيان المراجعين نجاح مثل هذه العمليات الجراحية وبدرجة كبيرة.