

Odontogenic Facial Cellulitis in Children: Review Article

Abdullah S. Al-Mushayt, PEDI CERT., PhD, **Zeinab E. Darwish**¹, PhD and **Narmin S. Helal**, BDS

Department of Preventive Dentistry, Division of Pediatric Dentistry

¹*Department of Oral Basic and Clinical Sciences, Division of Oral Pathology*

Faculty of Dentistry, King Abdulaziz University

Jeddah, Saudi Arabia

zenabelsayed@yahoo.com

Abstract. Facial cellulitis is a common clinical problem in pediatric patients. It is an infection of the skin that causes pain, swelling, and redness on the face. Additional symptoms include fever, chills, swollenness and tender tongue. Although the disease itself is not serious, it's important to get it treated promptly because it can cause serious complications. The main objective of this article is to review the literature and to emphasize the importance of establishing guidelines on the proper management of this condition. Diagnosis of facial cellulitis starts by history, overall assessment and local examination. In addition, panoramic radiograph, magnetic resonance imaging, ultrasonography and computed tomography could be considered as effective methods of detecting such cases. Hospital admission and the use of antibiotic should not always be the first management, since it is guarded by several limits. Simple management guidelines should include two major steps: removal of the cause and local drainage, and debridement. Previous studies found faster resolution of infection and less use of antibiotic is associated with early surgical drainage. Analgesics and nutritional support are mandatory. Although, the present review gives some high light on facial cellulitis in pediatric dentistry, more systematic reviews of literature are still needed in this point of interest.

Keywords: Facial cellulitis, Odontogenic infections, Cellulitis in children.

Correspondence & reprint request to: Prof. Zeinab Darwish
P.O. Box 80209, Jeddah 21589, Saudi Arabia

Accepted for publication: 15 October 2011. Received: 17 June 2011.

Introduction

Facial cellulitis is defined as an acute and edematous spread of an inflammatory process through the facial planes of the soft tissue. This usually occurs if an abscess is not able to establish drainage through the surface of the skin or into the oral cavity^[1]. Most reports regarding the management of dental infections are derived from studies in adults. Severe infections are common in young children; however, there is a paucity of data regarding the medical and surgical management of complicated dental infections in children. The management of facial cellulitis is still empirical. Our main objective of this article is to review the literature and to emphasize the importance of establishing guidelines on the proper management of such life threatening condition in children.

Types of Cellulitis

Cellulitis can be classified on the basis of location and evolution. On the basis of location, cellulitis can be classified to either upper face infection (UFI) or lower face infection (LFI). On the basis of evolution, cellulitis is divided into acute and chronic. Causes of infection can be categorized as odontogenic and non odontogenic.

Cellulitis is more likely to afflict the upper facial region (65%). Based on the etiology, odontogenic infection composed almost 50% of facial cellulitis as stated in the Pittsburg Children's hospital in the 80s. It has been mentioned in the literature that the location of the infection is important in the proper management of facial cellulitis^[2,3]. Biederman *et al.*^[2] found that children with UFI were younger, had more acute symptoms, an elevated white blood cell counts and the source of infection was commonly unknown with greater variability of cultured organisms. On the other hand, other studies^[4,5] found that children with LFI were generally older, with symptoms of more chronic nature. The source of infection could frequently be identified and the types of organisms cultured were less variable. However, Lin and Lu^[6] recently found no difference in age, symptoms of infection, first visit to the dentist or pediatrician, need and length of hospitalization, timing of surgical or dental interventions, need for incision and drainage, and management of the primary odontogenic origin when comparing upper with lower face infections. They claim that the difference in previous

authors' opinion was probably due to the inclusion of non odontogenic samples in their studies.

Comparison between Odontogenic and Non Odontogenic Infection

There are several clinical differences between odontogenic and non odontogenic infection. Odontogenic infections have a propensity for older children of mixed dentition stage. Non odontogenic cases generally have a higher WBC count and higher auxiliary temperatures. Most of the odontogenic and non odontogenic cases occur in Spring with mean febrile auxiliary temperature of ($> 36.5^{\circ}\text{C}$) on admission. The most commonly occurring organisms differ, with *Haemophilus influenzae* (*H. influenzae*) type B (36%) being found in the nonodontogenic group and alpha streptococcus (47%) in the odontogenic group^[7].

Causes and Microbiology of Odontogenic Cellulitis

The etiology of odontogenic infection is usually attributed to the endogenous flora of the mouth and the introduction of nonresident bacteria. Odontogenic infections are typically polymicrobial; however, anaerobes generally outnumber aerobes by at least four fold^[8]. The mixed aerobic-anaerobic composition of the bacteria involved in suppurative odontogenic infections is thought to be important in the pathogenesis of infection. It is caused by a very well defined pattern called "synergism" which means that different bacterial species with different bacterial virulence support or synergize each other to be more virulent and more destructive. Barclay^[9] stated that if bacteria involved in mixed odontogenic infections are isolated and transferred to healthy animals, they are incapable of producing the disease. This means a synergistic interdependence between aerobic and anaerobic bacteria is thought to be necessary for the development of infection. After the inoculation of aerobic bacteria in deep tissues, a proliferation transpires, the respiration of aerobic bacteria depletes the local environment of oxygen, which leads to a decrease in the reduction oxidation potential; making an oxygen poor, nutrient-rich habitat, thus creating the ideal environment for anaerobic bacteria to propagate, flourish and thrive, and then predominate. After anaerobiosis occurs, toxins and enzymes are secreted by the bacteria, which result in tissue destruction and abscess formation^[8].

Before the introduction of *H. influenzae* vaccine in the 1990s, facial cellulitis was primarily caused by *H. influenzae* type B and often accompanied by bacteremia and meningitis. After that, *Streptococcus pneumoniae* has become the most common cause of UFI^[10].

Biederman *et al.*^[2] found that in UFI *Streptococcus epidermidis* was the most frequent organism identified followed by *Staphylococcus aureus*, *Streptococcus pyogenes*, *Streptococcus viridans*, *H. influenzae* and then *Streptococcus pneumoniae*. LFI cultures showed that the most common organisms were *Staphylococcus aureus* followed by *Streptococcus pyogenes*. They claim that the source of UFI on average has unknown etiology, but usually associated with a predisposing condition, such as a recent upper respiratory infection, otitis media, sinus symptoms, and with more variable organisms. On the other hand, LFI source is frequently identified with less variable microorganisms and was claimed to be herpetic gingivostomatitis as the first source. Odontogenic infection was the second most common cause, followed by unknown etiology and trauma. Chow *et al.*^[11] study supports Biederman *et al.*^[2] study which declares that most organisms involved in infections of the head and neck are of odontogenic origin^[12]. He found that the most common organisms cultured were *Staphylococcus aureus* followed by *Staphylococcus pyogenes*. However, Unkel *et al.*^[7] claims that odontogenic infection composed almost 50% as stated earlier. In addition, an Odontogenic infection is very well recognized as a mixed poly-microbial infection (aerobic and anaerobic). These differences in the source of infection and type of microorganisms could be due to inclusion of non odontogenic samples, different culturing technique, or different host susceptibility to certain type of microorganisms. Some studies claim that gram positive cocci are the predominant bacteria and gram negative rods were the second most bacterial isolate^[12,13]. Viridans Streptococci is the predominant species as supported by multiple studies^[12-16]. Other studies show predominance of gram negative rods (*Bacteroids/Prevotella*)^[17-20].

Hiemdahl *et al.*^[21] examined orofacial infections and correlated their clinical appearance with the observed microbial etiology. Anaerobic gram negative rods, (*Bacteroids*, *Prevotella*, and *Fusobacterium*) were more frequently isolated from patients with severe infections than from those deemed to have mild infection. *Fusobacterium nucleatum* was predominantly associated with severe infections.

Facial cellulitis due to *S. pneumoniae* is rare^[22].

Anatomical Pathway of Spread

Good anatomy understanding is required to investigate the pathways of spread of infection, since there are five important spaces that play a major role in the infection spreading path which are: the masticator, sublingual, submandibular, parapharyngeal, and parotid space. Normal anatomic structures present in these spaces also play a role such as; masseter, buccinators, medial and lateral pterygoids, mylohyoid, and temporalis muscle structures like parotid gland, and deep cervical fascia might be included as well.

In the UFI the pathway of spread is similar regardless of the etiology. However, limited data were available regarding maxillary infection since it cannot be conclusively delineate its spread pattern. Maxillary molars infection spread laterally inferior to the buccinator attachment, and perforates the buccal plate (vestibular cortex) into the mucobuccal fold that may spread above the buccinators attachment into the soft tissue of the cheek. The former path of spread results in intraoral swelling, whereas the latter result in swelling of the cheek and periorbital tissues^[23] (Fig. 1).

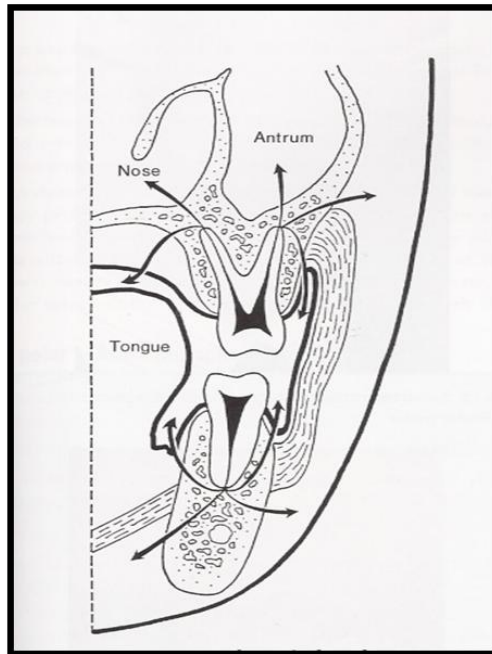


Fig. 1. The pathway of spreading of infection from the periapical area of upper and lower teeth is shown.

It may also produce secondary maxillary sinusitis with the swelling of the cheek and buccal sulcus as well as drainage from the nose. It may also spread posteriorly, in the buccal space to the pterygopalatine fissure and infratemporal fossa. Infection may then reach the orbit *via* the inferior orbital fissure, usually the canine causes infection in the infra orbital region as it has a long root (canine fossa). The roots of the upper lateral incisor and the palatal roots of the upper premolars and molars may be closer to the lingual cortex. Thus, that periapical infection of this tooth typically spreads towards the palate causing a submucosal abscess. Temporalis muscle was associated with maxillary infection more often than mandibular infection, and no cases in the literature were associated with sublingual or submandibular space^[24]. Generally, it spreads to the deep facial and neck spaces in a different way from that of mandibular infection.

In the LFI, accumulated pus perforates bone at the weakest and thinnest part of the bone, which is the lingual aspect of the molar region at the mandible^[11,25]. Yonestu *et al.*^[26] study showed that the masticator space is the most prevalent site of spread from the mandibular infection and it spreads directly to the sublingual and submandibular space. The parotid and the pharyngeal spaces are secondary sites of spread from the masticator space. This was the opposite of what was thought that it results mainly from parotitis. Infection spreads from the mandibular molars into the infratemporal fossa (posteriorly and medially) or into the buccal space (posteriorly and laterally). Medial spread of infection results in swelling of the floor of the mouth and elevation of the tongue. Ludwig's angina results when the submandibular and sublingual spaces on both sides of the midline are involved. When the submylohyoid space is involved it manifests as extra oral swelling. If the apical infections of the first lower molar, premolar, cuspid, and incisor propagate lingually above the insertion of the mylohyoid muscle, the sublingual space is affected. Lower incisors infection can lead to vestibular or mental abscess depending on the spread, whether above or below the insertion of the levator labii inferiors and if it spreads more caudally, the pus collects in the submental space. Lower premolars and first molars may cause abscess in the vestibule when infection cannot cross the buccinator muscle insertion. Whereas infections originating from second molars closer to the lingual cortex, generally disseminate medially towards the tongue below the insertion of the mylohyoid muscle involving the

submandibular space. If periapical infection of the lower premolars and molars disseminate laterally beneath the insertion of the buccinators muscle, they affect the superficial face spaces.

Stages of Infection

Infection has two stages: initial (serous) stage, which frequently develops into a subsequent (suppurative) phase. Initial stage starts by inoculation into deep tissues and then inflammation develops (acute cellulitis). The intensity and manifestation depends on the host defense, the anatomical location and the virulence of the bacteria. All of these play a role if illness evolves over a period of hours or days^[27].

Diagnosis and Management

Diagnosis of facial cellulitis starts by history of the evolution and duration of symptoms, current and prior illness. In addition to hypersensitivity to medication, medical treatments and surgical procedure previously attempted for the same condition as well as their effectiveness and the use of immunosuppressant drugs. Overall assessment is a must. Local examination must include visual inspection which enables the examiner to identify the cause and Palpation, which enables the examiner to assess the tissue consistency. It's important to note that UFI examination must include ophthalmic assessment.

Regarding the diagnosis, panoramic X-rays are the first option that helps to identify the cause of the condition. However, deep facial space involvement detection is very challenging. Magnetic resonance imaging has been used for localization of a maxillofacial infection^[27,28]. In addition, ultrasonography could be considered as an effective method of detecting and staging spread of odontogenic infections; however, deep facial space infections still difficult to detect using this method. Yonestu *et al.*^[26] found that CT is useful in the identification and evaluation of odontogenic facial and neck space infection.

Causes could be anything like sialolithiasis, fracture or caries, therefore, management should remove the cause whatever it maybe. In cases of odontogenic infections, management could be done on tooth extraction, root canal work, or periodontal therapy. Generally, odontogenic infections primarily require surgical treatment with antibiotic as co-adjunctive therapy. In localized infection it's not

indicated to use antibiotic, however, its mandatory when there are signs of dissemination or persistence of the septic process, fever, general malaise, regional lymphadenopathy or trismus.

Historically in the literature, penicillin had been used as the first line agent in the treatment of odontogenic infections, and the regimen used for treatment is: Amoxicillin/clavulanic acid 2000/125 mg one hour prior to starting surgical intervention, followed by 2000/125 mg every 12 hours for 5-7 days. Other alternative regimens include^[29]: Penicillin 2 g one hour prior to surgery followed by 500 mg every 6 hours for 5-7 days. If there is no response after 48 hours, consider the addition of 500 mg metronidazole every 8 hours or clindamycin, 300 mg every 6 hours (per os) for 5-7 days.

Since over 90% of odontogenic infections are caused by penicillin sensitive bacteria^[1], penicillin is still shown to be effective as an empirical drug of choice for odontogenic infections. However, increasing rates of penicillin resistance and treatment failures have been reported^[30-35]. Genus *Bacteroids* and *Prevotella* have been associated with the highest rates of penicillin resistance^[30,31,34]. Heimdahl *et al.*^[32] and Whitcher *et al.*^[33] reported that patients failing penicillin therapy was due to *Prevotella melaninogenicus* (*Bacteroids*). Clindamycin has a broad spectrum of coverage, excellent clinical activity and efficacy against gram positive organisms, including anaerobes and B-lactamase producing strains. According to this with the increase in both penicillin resistance and reports of treatment failures with penicillin, have prompted the Sanford Guide to Antimicrobial therapy to replace Penicillin V with Clindamycin as the drug of choice treating odontogenic infections in 1996^[36].

Gilmore *et al.*^[37] demonstrated comparable activity between Clindamycin and Penicillin V in the treatment of moderate to severe odontogenic infections. Furthermore, Von Konow *et al.*^[38] supported previous findings, but the patients treated with Clindamycin group had a shorter duration of fever, pain, and swelling. Finally, Rush *et al.*^[39] in 2007 supported earlier studies by stating that clindamycin and ampicillin/sulbactam or amoxicillin and clavulanate, when combined with surgical drainage are equally effective regimens in the treatment of odontogenic facial cellulitis and dental abscess in children.

There are no guidelines regarding the oral versus intravenous antibiotic. Most infections can be adequately managed using oral therapy when treated with timely manner. Patient with no air way swelling, eyelid swelling, or neck involvement, who have normal oral intake and systemically feel well, are good candidates for oral therapy. On the contrary, intravenous antibiotics and hospital admission should be strongly considered when swelling of the airway, swelling of the eyelid, or neck involvement is present, or patient's level of activity and oral intake is decreased.

Simple management guidelines should always cross our mind when first seen these patients, which include two major steps: removal of the cause and local drainage, and debridement.

Hospital admission and the use of antibiotic should not always be the first management, since it is guarded by several limits. Indication for pediatric children admission includes: (1) Signs of sepsis, such as fever, lymphadenopathy, elevated WBC, (2) poor oral intake, (3) doubt about the care they will receive at home, (4) the need for operation and (5) failure of outpatient management to resolve infection. Additional consideration of potential airway obstruction resulting from trismus swelling and elevation of the tongue, since elective endotracheal intubation or emergency tracheotomy^[10].

There are controversies regarding the delay of surgical manipulation in the presence of acute dentoalveolar infection to prevent life threatening complications and to allow more time for better localization of the abscess^[37]. Lin *et al.*^[6] study found that surgical or dental intervention can be delayed through the proper use of antibiotic. They claimed that young children have a better response to antibiotics than adults. Regardless, to depend entirely on that cannot be possible as children response to antibiotic is unpredictable. In addition, some children may have adverse effect from antibiotic that fails its effect. For example, gastroenteritis and vomiting are common side effect with oral antibiotics. Lin *et al.*^[6] did not discriminate in their sample between oral and IV administered antibiotic. Furthermore, previous studies found faster resolution of infection and less use of antibiotic is associated with early surgical drainage^[40]. Therefore, to delay the surgical intervention cannot be considered unless patient's condition is complicated to go under surgery.

Laboratory exudates cultures are not routinely performed, but this should be done on the following cases: (1) When the patient fails to respond to empirical antibiotic therapy and to treat the cause within 48 hours, (2) when it keeps disseminating despite the initial therapy, and (3) in immunocompromised patient if he or she has a prior history of bacterial endocarditic and does not respond to the initial antibiotic. Furthermore, analgesics and nutritional support are mandatory^[27].

Referral to the maxillofacial surgeon should be done by the pediatric dentist when infection is spreading to the fascial spaces with risk of dehydration, functional impotence, breathing impairment or spreading to the chest, eye socket or intracranial.

Complications

The common systemic complications of infections are sepsis and dehydration. Regardless of the etiology, serious complication of the upper facial region has become very rare. These complications could be orbital cellulitis, cavernous sinus thrombosis, meningitis, and blindness. These complications occur when infection spread to the central nervous systems or orbit through the local tissue planes or retrograde through the valveless facial and angular veins^[10,41-49]. In the LFI, the potential airway obstruction resulting from trismus, swelling and elevation of the tongue (Ludwig's angina) should be given an additional consideration.

Summary and Conclusion

Odontogenic infections are known as polymicrobial infections; however, anaerobes generally outnumber aerobes by at least four folds. The mixed aerobic-anaerobic composition of the bacteria involved in suppurative odontogenic infections is thought to be important in the pathogenesis of facial cellulitis.

Diagnosis of facial cellulitis starts by history and an overall assessment is a must. Local examination must include visual inspection and palpation. Regarding the diagnosis, panoramic X-rays are the first option that helps to identify the cause of the condition. However, deep facial space involvement detection is very challenging. Magnetic resonance imaging has been used for localization of a maxillofacial infection. In addition, ultrasonography and CT could be considered as an effective method of detecting such cases.

Odontogenic infections primarily require surgical treatment with antibiotic as co-adjunctive therapy. Simple management guidelines should always be considered when first seeing these patients, which include two major steps: removal of the cause and local drainage, and debridement.

Hospital admission and the use of antibiotic should not always be the first management, since it is guarded by several limits. Previous studies found faster resolution of infection and less use of antibiotic is associated with early surgical drainage. Analgesics and nutritional support are mandatory.

Recommendation

More systematic reviews of literature are needed and evidence-based dentistry, which is the gold standard for any clinician. Thus, is still needed in this point of interest.

References

- [1] **Neville BW, Damm DD, Allen CM, Bouquot JE.** *Oral and Maxillofacial Pathology*. 3rd ed, Philadelphia, USA: Saunders Elsevier, 2009. 138-141.
- [2] **Biederman GR, Dodson TB.** Epidemiologic review of facial infections in hospitalized pediatric patients. *J Oral Maxillofac Surg* 1994; **52**(10): 1042-1045.
- [3] **Dadson TB, Barton JA, Kaban LB.** Predictors of outcome in children hospitalized with maxillofacial infections: A linear logistic model. *J Oral Maxillofac Surg* 1991; **49**(8): 838-842.
- [4] **Starchan DD, Williams FA, Bacon WJ.** Diagnosis and treatment of pediatric maxillofacial infections. *Gen Dent* 1998; **46**(2): 180-182.
- [5] **Grossman M.** Management of the febrile patient. *Pediatr Infect Dis J* 1986; **5**(6): 730-734.
- [6] **Lin YT, Lu PW.** Retrospective study of pediatric facial cellulitis of odontogenic origin. *Pediatr Infect Dis J* 2006; **25**(4): 339-342.
- [7] **Unkel GH, McKibben DH, Fenton SJ, Nazif MM, Moursi A, Schuit K.** Comparison of odontogenic and non odontogenic facial cellulitis in pediatric hospital population. *Pediatr Dent* 1997; **19**(8): 476-479.
- [8] **Sandor GK, Low DE, Judd PL, Davidson RJ.** Antimicrobial treatment options in the management of odontogenic infections. *J Can Dent Assoc* 1998; **64**(7): 508-514.
- [9] **Barclay JK.** Antibiotic revisited. *N Z Dent J* 1990; **86**(384): 44-47.
- [10] **Dadson TB, Perrott DH, Kaban LB.** Pediatric maxillofacial infection: retrospective study of 113 patients. *J Oral Maxillofac Surg* 1989; **47**(4): 327-330.
- [11] **Chow AW, Roser SM, Brady FA.** Orofacial odontogenic infection. *Ann Intern Med* 1978; **88**(3): 392-402.
- [12] **Storoe W, Haug RH, Lillich TT.** The changing face of odontogenic infections. *J Oral Maxillofac Surg* 2001; **59**(7): 739-748.

- [13] **Rega AJ, Aziz SR, Ziccardi VB.** Microbiology and antibiotic sensitivities of head and neck space infection of odontogenic origin. *J Oral Maxillofac Surg* 2006; **64**(9): 1377-1380.
- [14] **Labriola JD, Mascaro J, Alpert B.** The microbiologic flora of orofacial abscess. *J Oral Maxillofac Surg* 1983; **41**(11): 711-714.
- [15] **Hunt DE, Meyer RA.** Continued evolution of the microbiology of oral infection. *J Am Dent Assoc* 1983; **107**(1): 52-54.
- [16] **Bartlett JG, O'Keef P.** The bacteriology of perimandibular space. *J Oral Surg* 1979; **37**(6): 407-409.
- [17] **Kannagara DW, Thadepalli H, Mcquirter JL.** Bacteriology and treatment of dental infection. *Oral Surg Oral Med Oral Pathol* 1980; **50**(2): 103-109.
- [18] **Brook I, Frazier EH, Thompson DH.** Aerobic and anaerobic microbiology of peritonsillar abscess. *Laryngoscope* 1991; **101**(3): 289-292.
- [19] **Sakaguchi M, Sato S, Ishiyama T, Katasuno S, Taguchi K.** Characterization and management of deep neck infections. *Int J Oral Maxillofac Surg* 1997; **26**(2): 131-134.
- [20] **Har-EI G, Aroesty JH, Shaha A, Lucente FE.** Changing trends in deep neck abscess. A retrospective study of 110 patients. *Oral Surg Oral Med Oral Pathol* 1994; **77**(5): 446-450.
- [21] **Heimdahl A, Von konow L, Sato T, Nord CE.** Clinical appearance of orofacial infections of odontogenic origin in relation to microbiological findings. *J Clin Microbiol* 1985; **22**(2): 299-302.
- [22] **Fisher RG, Benjamin DK Jr.** Facial cellulitis in childhood: a changing spectrum. *South Med J* 2002; **95**(7): 672-674.
- [23] **Nyberg DA, Jefferey RB, Brant-Zawadzki M, Federle M, Dillon W.** Computed tomography of cervical infections. *J Comput Assist Tomogr* 1985; **9**(2): 288-296.
- [24] **Soames JV, Southam JC.** Oral Pathology, 4th ed, chp 5. UK: Oxford Med Pub, 2005. 62.
- [25] **Mitchell CS, Nelson MD Jr.** Orofacial abscesses of odontogenic origin in the pediatric patient. Report of two cases. *Pediatr Radiol* 1993; **23**(6): 432-344.
- [26] **Yonetsu K, Izumi M, Nakamura T.** Deep facial infections of odontogenic origin: CT assessment of pathways of space involvement. *AJNR Am J Neuroradiol* 1998; **19**(1): 123-128.
- [27] **De-Vicente-Rodriguez JC.** Maxillofacial cellulitis. *Med Oral Patol Oral Cir Bucal* 2004; **9**(Suppl.): 133-138; 126-133.
- [28] **Fielding AF, Reck SF, Barker WJ.** Use of magnetic resonance imaging for localization of a maxillofacial infection: report of a case. *J Oral Maxillofac Surg* 1987; **45**(6): 548-550.
- [29] **Swift JQ, Gulden WS.** Antibiotic therapy--managing odontogenic infections. *Dent Clin North Am* 2002; **46**(4): 623-633.
- [30] **Murray PR, Rosenblatt JE.** Penicillin resistance and penicillinase production in clinical isolates of *Bacteroides melaninogenicus*. *Antimicrob Agents Chemother* 1977; **11**(4): 605-608.
- [31] **Kinder SA, Holt SC, Korman KS.** Penicillin resistance in the subgingival microbiota associated with adult periodontitis. *J Clin Microbiol* 1986; **23**(6): 1127-1133.
- [32] **Heimdahl A, von Konow L, Nord CE.** Isolation of beta-lactamase-producing *Bacteroides* strains associated with clinical failures with penicillin treatment of human orofacial infections. *Arch Oral Biol* 1980; **25**(10): 689-692.
- [33] **Whitcher BL, Beirne OR, Smith RA.** Beta-lactamase-producing *Bacteroides melaninogenicus* and osteomyelitis of the mandible. *J Oral Med* 1983; **38**(1): 17-20.

- [34] **Edson RS, Rosenblatt JE, Lee DT.** Recent experience with antimicrobial susceptibility of anaerobic bacteria: increasing resistance to penicillin. *Mayo Clin Proc* 1982; **57**(12): 737-741.
- [35] **Walker C, Gorden J.** The effect of clindamycin on microbiota associated with refractory periodontitis. *J Periodontol* 1990; **61**(11): 692-698.
- [36] **Chiang SR, Chuang YC.** *Vibrio vulnificus* infection: clinical manifestations, pathogenesis, and antimicrobial therapy. *J Microbiol Immunol Infect* 2003; **36**(2): 81-88.
- [37] **Gilmore WC, Jacobous NV, Gorbach SL.** A prospective double blind evaluation of penicillin versus clindamycin in the treatment of odontogenic infections. *J Oral Maxillofac Surg* 1988; **46**(12): 1065-1070.
- [38] **Von Konow L, Kondell PA, Nord CE.** Clindamycin versus phenoxymethylpenicillin in the treatment of acute orofacial infections. *Eur J Clin Microbiol Infect Dis* 1992; **11**(12): 1129-1135.
- [39] **Rush DE, Abdel-Haq N, Zhu J.F, Aamar B, Malian M.** Clindamycin versus Unasyn in the treatment of facial cellulitis of odontogenic origin in children. *Clin Pediatr (Phila)* 2007; **46**(2): 154-159.
- [40] **Bridgeman A, Wielesenfeld D, Hellyar A, Sheldon W.** Major maxillofacial infections. An evaluation of 107 cases. *Aust Dent J* 1995; **40**(5): 281-288.
- [41] **Kaban LB.** Draining skin lesions of dental origin: the path of spread of chronic odontogenic infection. *Plast Reconstr Surg* 1980; **66**(5): 711-717.
- [42] **Kaban LB. and McGill T.** Orbital cellulitis of dental origin: differential diagnosis and the use of computed tomography as a diagnostic aid. *J Oral Surg* 1980; **38**(9): 682-685.
- [43] **Lessner A, Stern GA.** Preseptal and orbital cellulitis. *Infect Dis Clin North Am* 1992; **6**(4): 933-952.
- [44] **Jain A, Rubin PA.** Orbital cellulitis in children. *Int Ophthalmol Clin* 2001; **41**(4): 71-86.
- [45] **Brook I, Friedman EM, Rodriguez WJ, Controni G.** Complications of sinusitis in children. *Pediatrics* 1980; **66**(4): 568-527.
- [46] **Watters EC, Wallar PH, Hiles DA, Michaels RH.** Acute orbital cellulitis. *Arch Ophthalmol* 1976; **94**(5): 785-788.
- [47] **Donahue SP, Khoury JM, Kowalski RP.** Common ocular infections: a prescriber guide. *Drugs* 1996; **52**(4): 526-540.
- [48] **Uzcategui N, Warman R, Smith A, Howard CW.** Clinical practice guidelines for the management of orbital cellulitis. *J Pediatr Ophthalmol Strabismus* 1998; **35**(2): 73-79.
- [49] **Kiddee W, Preechawai P, Hirunpat S.** Bilateral septic cavernous sinus thrombosis following the masticator and parapharyngeal space infection from the odontogenic origin: a case report. *J Med Assoc Thai* 2010; **93**(9): 1107-1111.

مراجعة لالتهاب السني للنسيج الخلوي الوجهي في الأطفال

عبد الله سعيد المشيط، و زينب السيد درويش¹، و نرمين سعيد هلال

قسم شعبة طب أسنان الأطفال و شعبة أمراض الفم¹

كلية طب الأسنان ، جامعة الملك عبدالعزيز

جدة - المملكة العربية السعودية

المستخلص. يشكل التهاب النسيج الخلوي للوجه مشكلة إكلينيكية في طب الأطفال. وهو عبارة عن عدوى الجلد التي تسبب الألم وتورم واحمرار الوجه بالإضافة إلى الحمى ولتهيج وتورم اللسان. رغم أن المرض نفسه ليس خطيراً، فإنه من المهم التعامل معه على الفور لأنه يمكن أن يتسبب في مضاعفات خطيرة. كان الهدف الرئيسي لهذه المراجعة البحثية هو استعراض الكتابات، والتركيز على أهمية وضع مبادئ توجيهية بشأن المعاملة السليمة لهذه الحالة. يبدأ تشخيص الالتهاب الخلوي للوجه بمعرفة تاريخ المرض والتقييم الشامل وبالإضافة إلى الفحص الموضوعي، يمكن عمل أشعة سينية بانورامية، يعتبر التصوير بالرنين المغناطيسي والموجات فوق الصوتية والتصوير المقطعي وسائل فعالة للكشف على مثل هذه الحالات. لا يعتبر دخول المستشفى واستخدام المضادات الحيوية هو الوسيلة الأولى للتحكم في المرض، وينبغي أن تشمل مبادئ العلاج البسيط خطوتين رئيسيتين هما: زوال سبب المرض وتصريف الصديد إن وجد. وجدت الدراسات السابقة أن التخلص من العدوى من خلال التصريف الجراحي للصدید يؤدي للتحسن السريع باستخدام مضاد حيوى أقل. يعتبر تناول المسكنات والدعم الغذائي مهم لعلاج هذه

الحالة. على الرغم من أن هذا الاستعراض يلقى بعض الضوء على التهاب النسيج الخلوي للوجه في طب أسنان الأطفال، فإنه لا تزال هناك حاجة في استعراض أكبر وأشمل للمراجع التي تتناول هذه النقطة المثيرة للاهتمام.