

## **Balloon Atrial Septostomy in Patient with Dextrotransposition of the Great Arteries with Insufficient Mixing: 18 years Experience**

**Jameel A. Al-Ata, FRC(P)**

*Department of Pediatric, Faculty of Medicine  
King Abdulaziz University,  
Jeddah, Saudi Arabia  
drjameelalata@hotmail.com*

*Abstract.* This study presents 18 years experience (1987 to 2005) of balloon atrial septostomy in patients with d- transposition of the great arteries. Forty-four patients underwent this procedure, under echocardiographic (Group A, n = 19) and fluoroscopic guidance (Group B, n = 25). The atrial septal defect size and oxygen saturation, before and after the procedure were compared in all as well as in Groups A and B. The atrial septal defect and oxygen saturation increased in all; from means of  $2.3 \pm 0.6$  mm,  $48 \pm 8\%$  to  $4.9 \pm 1.3$  mm and  $72 \pm 16.3\%$  after the procedure with statistical significance. Both variables increased in the two groups independently with statistical significance. Transient arrhythmias were encountered in 3 patients and balloon ruptured in one, without any sequel. One had respiratory arrest after morphine administration and required temporary intubation. One patient died due to cardiac tamponade and another due to hepatic vein perforation. Two late presenters expired due to persistent metabolic acidosis even after successful procedure. Therefore, this concludes that balloon atrial septostomy is a safe, effective and life saving palliation, and serves as a bridge for surgical intervention. It is equally effective under fluoroscopic and echocardiograph monitoring.

*Keywords:* Balloon atrial septostomy, Transposition of the great arteries, Prostaglandin E1.

---

Correspondence & reprint request to:

Dr. Jameel A. Al-Ata  
P.O. Box 80215, Jeddah 21589, Saudi Arabia

Accepted for publication: 30 May 2010. Received: 16 January 2010.

## Introduction

Cyanotic congenital heart defects such as Dextrotransposition of the Great Arteries, tricuspid atresia, pulmonary atresia, total anomalous pulmonary venous drainage, and hypoplastic left heart syndrome require an obligatory and non-restrictive mixing of blood at the atrial level to sustain life<sup>[1-3]</sup>. The presence of a small and restrictive atrial septal defect (ASD) in the presence of above congenital heart defect, and the resultant inadequate mixing of blood, results in persistent hypoxia and metabolic acidosis. Life could still be sustained by continuous infusion of Prostaglandin (PGE1) to maintain patency of the arterial duct. A palliative procedure, like creation of ASD or increasing the size of already existing patent foramen ovale (PFO) would provide a 2<sup>nd</sup> mixing site at the atrial level. Surgical creation of an ASD was first described by Blalock and Hanlon in 1950<sup>[4]</sup>. Afterwards, Rashkind and Miller performed this procedure in the hemodynamic laboratory with the help of a balloon catheter without requiring a thoracotomy<sup>[5]</sup>. It was Perry *et al.* who used echocardiography to assist in locating the venous or arterial catheters in infants and children<sup>[6]</sup>. Matsunaga and his colleagues from Japan, were the first to report in applying echocardiographic monitoring for balloon atrial septostomy(BAS)<sup>[7]</sup>. This report was followed by other reports from Allen *et al.*<sup>[8]</sup>, and subsequently by Perry *et al.*<sup>[9]</sup>. Later on, it was Baker and colleagues who reported performing of BAS at bedside<sup>[10]</sup>.

### ***Objectives of the Study***

The objective of this review was to assess the efficacy and safety of balloon atrial septostomy, as well as to compare efficacy and safety of fluoroscopic and echocardiographic monitoring of the procedure.

## Patients and Methodology

### ***Patient Population***

The medical records of 113 patients with D-TGA were reviewed, retrospectively. Forty-four patients who underwent BAS either in the NICU or in the cardiac catheterization laboratory were included in the study. They were divided into two groups based on echocardiographic (Group A) or fluoroscopic (Group B) monitoring. The demographic

data, including the gestational age, the birth weight and complete diagnosis was also noted. The venous access was also documented.

The ASD/PFO size and oxygen saturation, before (condition I) and after (condition II) BAS was also noted. All complications during or after the procedure were also reviewed.

### ***Atrial Septostomy Balloon Catheters***

There are two types of septostomy catheters available for use. One is Z-5™ Atrioseptostomy catheter (NuMED, Canada Inc., Ontario, Canada). It is a double lumen catheter, in which the central lumen is an end-hole used for advancing the guide wire, while the outer hole communicates with the balloon and is used to inflate the balloon. It comes in 2 different sizes: shaft of 4 and 5 F, which require 5 and 6 F introducers, respectively. The usable length for both of these is 50 cm. The 4F catheter takes 1.0 cc fluid and attains a maximum diameter of 9.5 mm, while the 5 F catheter takes 2 cc fluids and attains a maximum diameter of 13.5 mm.

The second catheter is the Rashkind Septostomy Balloon Catheter (Medtronic, Danvers, MA). It is a single lumen catheter, and the only one used to inflate the balloon. It comes in three different sizes: The shaft size of 4, 5 and 6 F's (need 6, 7, and 8F introducers, respectively). The usable length is 50 cm for all of the sizes. The balloons can accommodate to a volume of 1.0, 1.5, & 2 cc and inflate to a maximum diameter of 11, 12, & 14 mm, respectively.

### ***Balloon Atrial Septostomy***

A written consent was obtained either from the parents or from the attendants according to the bylaws of the hospital. The procedure was carried out under conscious sedation by using either oral Chloral Hydrate: 50 mg/kg given 15 min before the procedure, or intravenous midazolam: 0.1 mg/kg/dose, given just before the procedure. In five patients, intra-venous morphine (0.1 mg/kg) was additionally given to help in sedating the patients. Local analgesia was given using 2% lidocaine infiltrated in the inguinal region. The patients were prepped and draped in a sterile manner. The vascular access was obtained either in the femoral or the umbilical vein. Rashkind Balloon Septostomy Catheter (5 or 6 F) was introduced and was advanced to the inferior vena

cava, either under echo-guidance in the NICU or under fluoroscopic monitoring in the catheterization laboratory. Sub-costal coronal or off-axis views were used to view the atrial septum echocardiograph. The catheter was then advanced to the right atrium, and finally to the left atrium through the patent foramen ovale. Once the position of the catheter confirmed in the left atrium and away from the pulmonary veins and mitral valve, the balloon was then inflated with 2 to 2.5 cc of normal saline. Finally, while holding close to the point of entry in the body, the catheter was pulled back suddenly in a jerky manner, using wrist joint to produce jerks while the elbow joint being stabilized and fixed at the same time. Two to three pulls were attempted in each patient. The resultant size of the ASD was measured, and the flow across it was confirmed echocardiographically using 2-D, as well as color Doppler mode. The ASD size was measured on 2-D as well as on color Doppler mode during both the conditions. Sub-costal coronal echocardiography view was used to assess the inter-atrial septum, the mitral valve and the left ventricular inlet. Three readings were taken and the mathematical average was calculated. None of the patients were heparinized and antibiotic was not administered to anyone. The Rashkind Balloon Septostomy Catheter was introduced through the umbilical vein in 25 patients and through the femoral vein in 18 patients; in one patient femoral cut down was needed. All complications encountered were also documented.

### ***Echocardiographic Evaluation of ASD***

For the purpose of sizing of the ASDs produced, all of the echocardiograms were reviewed individually and by the same reviewer to minimize the individual variation.

### ***Complications***

Complications were graded as minor, if did not require any intervention to revert back to normal or if didn't result in permanent damage or debility. These were graded as major; if some intervention was required in reverted the condition to normal, or if it resulted in permanent damage, debility or death.

### ***Statistical Methods***

Independent sample "student's" *t* test was applied to match the two groups for two variables during both the conditions. Paired sample

“student’s” *t* test was applied to compare the two variables during condition I and II in all of the patients as one group, and also in the two groups independently. The data was presented as mean  $\pm$  standard deviation (SD); the range was also provided (in brackets).

## Results

### *Demographic and Clinical Data*

Forty-four of 113 patients fulfilled the criteria for inclusion in the study. The demographic data and the diagnostic details of the patients are presented in Table 1. The detailed variables are presented in Table 2. All patients were full term with the mean gestational age of  $39.3 \pm 1.2$  weeks (37-41), and mean birth weight of  $3.2 \pm 0.5$  kg (2.3-4.1). The procedure was carried out in 19 (43%) patients in the referring hospital. Trans-femoral approach was utilized in 19 patients while trans-umbilical in the rest of them. 19 patients underwent BAS under echocardiographic monitoring at the bedside in the NICU, while fluoroscopic monitoring was used in the rest of the cases.

**Table 1. Demographic and clinical data.**

Sex		Gestational age Mean $\pm$ SD (range)	Birth weight Mean $\pm$ SD (range)	Diagnosis, D-TGA with			
M	F	Weeks	Kilograms	IVS	PFO/ASD	VSD	PDA
24	20	$39.3 \pm 1.2$ (37-41)	$3.2 \pm 0.5$ (2.3-4.1)	20	13	8	7*

\*Four patients had VSD also

Abbreviations: M = Males, F = Females, IVS = Intact Ventricular Septum, PFO = Patent Foramen Ovale, ASD = Atrial Septal Defect, VSD = Ventricular Septal Defect, PDA = Patent Ductus Arteriosus.

**Table 2. Variables of the patients.**

Pt	Place	PGE1	Access	ASD I	ASD-II	Sat I	Sat II	Comp
1	Cath	Yes	Umb	2	5	50	69	None
2	Cath	Yes	Umb	3	5	45	68	None
3	Bed	Yes	Umb	3	6	55	70	None
4	Cath	Yes	Umb	2	5	45	78	<i>NSSVT</i>
5	Bed	Yes	Fem	2	5	40	72	None
6	Cath	Yes	Fem	2	--	45	--	<b>Death/Tamponade</b>
7	Bed	Yes	Umb	2	4	50	71	None
8	Bed	Yes	Umb	2	6	55	77	None
9	Cath	Yes	Umb	2	5	55	74	<b>TBR</b>

Table 2. Cont'd.

Pt	Place	PGE1	Access	ASD I	ASD-II	Sat I	Sat II	Comp
10	Cath	Yes	Fem	2	6	40	79	None
11	Bed	No	Umb	2	4	57	80	None
12	Cath	Yes	Umb	2	5	45	80	None
13	Bed	Yes	Umb	2	5	51	80	None
14	Cath	Yes	Fem	3	4	51	76	None
15	Cath	Yes	Fem	3	5	54	75	<b>NSSVT</b>
16	Bed	Yes	Umb	2	4	52	77	None
17	Cath	Yes	Fem	3	4	55	80	None
18	Bed	Yes	Umb	3	4	55	74	None
19	Bed	Yes	Umb	2	6	40	73	<b>TBR</b>
20	Bed	Yes	Umb	2	5	54	75	<b>Respiratory arrest</b>
21	Cath	No	Fem	3	6	57	76	None
22	Cath	Yes	Fem	2	5	54	78	None
23	Cath	Yes	Umb	2	--	55	--	<b>Death/H.V perforation</b>
24	Bed	Yes	Umb	2	6	51	76	None
25	Cath	Yes	Fem	2	5	52	77	None
26	Cath	Yes	Fem	2	5	52	74	None
27	Bed	Yes	Umb	2	5	44	78	None
28	Cath	Yes	Fem	2	6	47	79	<b>NSSVT</b>
29	Bed	Yes	Umb	2	5	35	80	<b>Balloon ruptured</b>
30	Cath	Yes	Fem	3	4	33	80	None
31	Cath	Yes	Fem	2	5	44	74	None
32	Bed	Yes	Umb	2	5	45	85	None
33	Bed	Yes	Umb	3	4	42	83	None
34	Cath	Yes	Fem	3	6	44	77	None
35	Cath	Yes	Fem	3	6	40	75	None
36	Bed	Yes	Umb	2	6	39	76	None
37	Cath	Yes	Fem	3	6	43	75	None
38	Bed	Yes	Umb	3	6	38	84	None
39	Bed	Yes	Umb	2	6	44	74	None
40	Cath	Yes	Fem	3	5	43	80	None
41	Cath	Yes	Fem	3	5	47	73	None
42	Cath	Yes	Fem	3	5	39	81	<b>TBR</b>
43	Bed	Yes	Umb	2	5	44	82	None
44	Cath	Yes	Umb	1	4	45	84	None

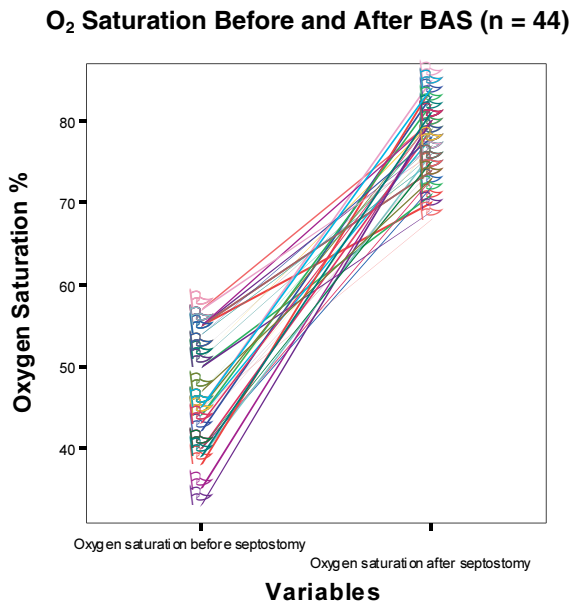
Abbreviations: Bed = Bedside, Fem = Femoral, Umb = Umbilical, NSSVT = Non-sustained Supraventricular Tachycardia, TBR = Transient Bradycardia, H.V = Hepatic Vein.

### ***Oxygen Saturation and ASD Size***

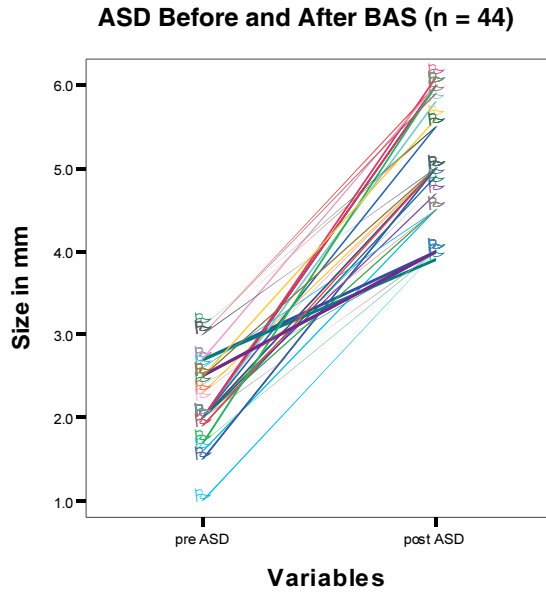
Figure 1 through 6 shows the oxygen saturation and the ASD size before and after the septostomy in the entire patient as one group (Fig. 1, 2), in the echo group (Fig. 3, 4) and finally, in the cath group (Fig. 5, 6). Table 3 shows that the two groups matched for ASD size and oxygen saturation under two conditions. Table 4 shows that the mean ASD size and mean oxygen saturation in all of the patients increased from  $2.3 \pm 0.5$  mm (1-3) and  $47 \pm 6.4$  % (33-57), respectively; during condition I to  $5.1 \pm 0.7$  mm (4-6) and  $77 \pm 4\%$  (68-85) during condition II, respectively, and the difference reached statistical significance. In the same way, both variables increased in Group A and Group B independently during condition II as compared during condition I, and the difference reached statistical significance.

### ***Discontinuation of Prostaglandin***

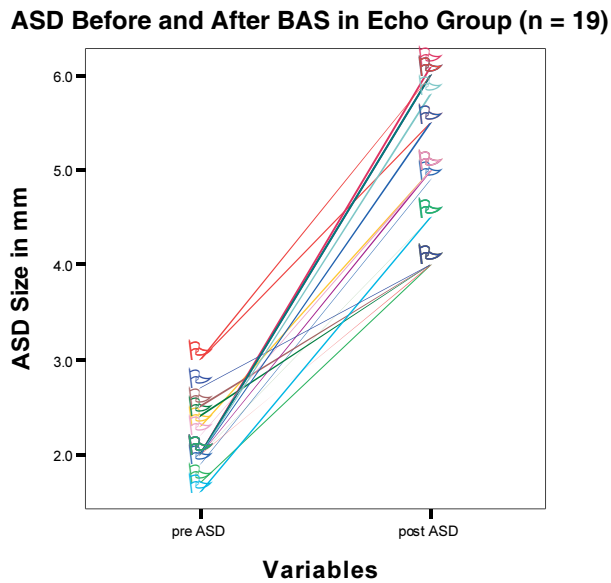
Forty-two patients were receiving PGE1 when septostomy was carried out. It was discontinued in 14 patients immediately after the procedure, while slowly weaned down in 24 h on the rest of them.



**Fig. 1. Significant increase in oxygen saturation after balloon atrial septostomy in all of the patients ( $p = 0.00$ ).**



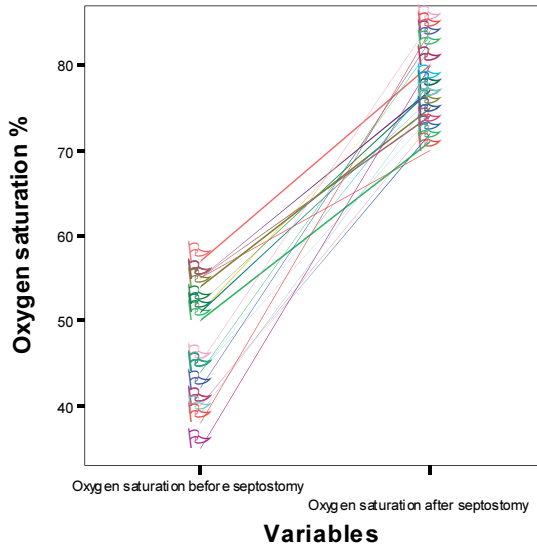
**Fig. 2.** Significant increase in atrial septal defect size after balloon atrial septostomy in all of the patients ( $p = 0.00$ ).



**Fig. 3.** Significant increase in atrial septal defect size after balloon atrial septostomy in echo group ( $p = 0.00$ ).

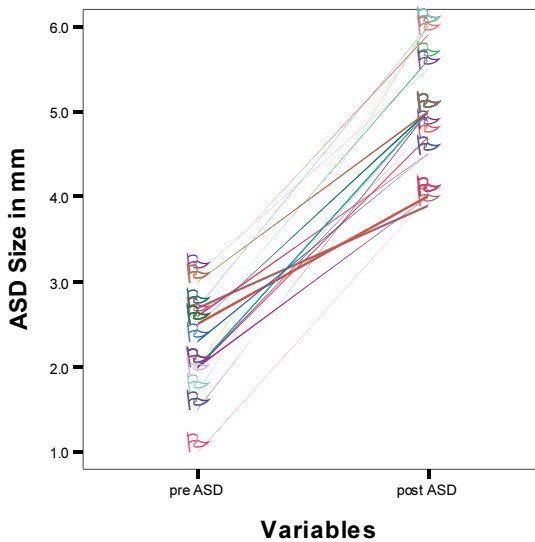


**O<sub>2</sub> Saturation Before and After BAS in Echo group (n = 19)**



**Fig. 4. Significant increase in oxygen saturation after balloon atrial septostomy in echo group (p = 0.00).**

**ASD Before and After BAS in Cath group (n = 23)**



**Fig. 5. Significant increase in atrial septal defect size after balloon atrial septostomy in cath group (p = 0.000).**

### O<sub>2</sub> Saturation Before and After BAS in Cath group (n = 23)

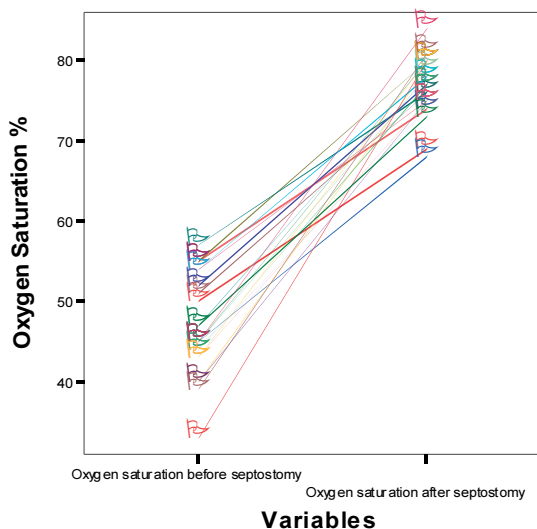


Fig. 6. Significant increase in oxygen saturation after balloon atrial septostomy in cath group ( $p = 00000$ ).

Table 3. The two groups matched for ASD size and oxygen saturation under two conditions.

Monitoring	ASD (mm)		Saturation (%)	
	Condition I	Condition II	Condition I	Condition II
Echo-guided	2.2 ± 0.4 (2-3)	5.1 ± 0.8 (4-6)	47 ± 6.9 (35-57)	77 ± 4.4 (70-85)
Cath-guided	2.4 ± 0.6 (1-3)	5.1 ± 0.6 (4-6)	47 ± 6.1 (33-57)	77 ± 3.7 (68-84)
p value	0.55	0.90	0.37	0.49

Abbreviations: ASD = Atrial Septal Defect, Condition I = Before Septostomy, Condition II = Post -Septostomy

Table 4. ASD and Oxygen saturation before and after septostomy in both groups

	Both Groups			Echo Group			Cath Group		
	Pre (n = 44)	Post (n = 42)	P	Pre (n = 19)	Post (n = 19)	P	Pre (n = 25)	Post (n = 23)	P
PFO/A SD (mm)	2.3 ± 0.5 (1-3)	5.1 ± 0.7 (4-6)	0.00	2.3 ± 0.4 (2-3)	5.1 ± 0.8 (4-6)	0.00	2.4 ± 0.6 (1-3)	5.1 ± 0.6 (4-6)	0.00
O <sub>2</sub> Sat. (%)	47 ± 6.4 (33-57)	77 ± 4 (68-85)	0.00	47 ± 7 (35-57)	77 ± 4.4 (70-85)	0.00	47 ± 6.1 (33-57)	76 ± 3.8 (68-84)	0.00

### Minor Complications

Minor complications were encountered in 7 patients. The details are shown in Table 2. Transient, self-limiting, bradycardia and supra-

ventricular tachycardia were each encountered in 3 patients, while the septostomy balloon ruptured in one, but without any consequences.

### ***Major Complications***

One patient developed respiratory arrest after morphine administration and needed assisted ventilation. Afterwards, the patient was safely extubated. Two deaths were encountered. One patient was a full term infant with D-TGA and intact ventricular septum with a baseline PFO size of 2 mm and oxygen saturation of 45% on room air. He was on prostaglandin infusion when the procedure was carried out. Femoral venous access was obtained. Difficulty was faced while crossing the PFO. A Terumo non-exchange guide wire (0.032 inches and 150 cm long) was introduced in the septostomy catheter to make it stiffer to assist in maneuverability. Multiple unsuccessful attempts were made to cross the PFO. In the process, patient started to develop tachyarrhythmia, followed by bradycardia, and hypotension. Sonographic evaluation confirmed significant pericardial effusion and signs of tamponade. He was shifted to ICU, where pericardial taping was done. Oxygen saturation decreased to 30% and blood gas analysis showed metabolic acidosis. He was intubated and put on assisted ventilation. Pack cell transfusion was also given. The condition didn't improve and the patient expired, 4 h after the procedure.

The other patient was the product of 38 weeks gestation, weighing 2.5 kg and diagnosis of D-TGA and IVS. His baseline saturation was 55% on nasal cannula oxygen of 3 l/min. Umbilical vein was cannulated and some difficulty was felt while passing the septostomy catheter through to the heart. The patient arrested while manipulating the catheter further deep inside. Sonographic evidence suggested hepatic venous perforation. The patient was intubated and shifted to the intensive care unit. Every effort was made to save the life, but he succumbed to the damage and could not be revived.

Two more patients (patient No. 19 and 36) expired due to persistent metabolic acidosis, even after successful BAS without any procedure related complications. One of them was a 25 days old boy who had D-TGA with IVS. He was sick, ventilated and was on PGE1 since birth in an outside hospital. He had baseline oxygen saturation around 30-40% and severe metabolic acidosis. His condition did not allow a transfer to

another hospital; therefore, BAS was carried out successfully in the same hospital at the bedside. The ASD size immediately after the procedure was measured to about 6 mm and the oxygen saturation increased to 73%. The improved oxygen saturation could not be sustained and severe metabolic acidosis could not be improved. During the next 48 hrs, his oxygen saturation ranged between 50-65% and he expired 3 days after the procedure. The other child was a late presenter, 6 months old, who had D-TGA with tiny VSD, a small PDA, and a 2 mm PFO. He had been admitted in an outside hospital for the last one month due to severe hypoxia, oxygen desaturation, and metabolic acidosis. He was intubated 3 days before the BAS. His baseline oxygen saturation was about 40% on room air. BAS was successfully carried out. The ASD size increased to 6 mm, and the oxygen saturation improved. However, metabolic acidosis persisted and patient kept deteriorating during next 48 hours and died.

### **Discussion**

BAS is a life saving procedure in cases of D-TGAs with intact septum. It is carried out when the surgical intervention is either not available, or is contraindicated due to other cardiac or non-cardiac reasons. It can also be carried out, either under echocardiographic guidance at the bedside or under fluoroscopic guidance in the cardiac catheterization laboratory. Thus, results in an adequate size ASD and provides effective mixing of blood to maintain acceptable oxygen saturation to bail out time; till the surgical intervention is planned.

#### ***Success and Efficacy of BAS***

The efficacy of BAS can be assessed using echocardiographic measurement of interatrial communication, hemodynamic criteria such as equalization of inter-atrial pressures, and clinical improvement in the patient's condition. The studies have shown successful BAS, both under echo and fluoro guidance. The oxygen saturation in majority of our patients (95%) improved to > 75% on room air after the procedure. Both the increase in the atrial septal defect size and the elevation in the arterial oxygen saturation were statistically significant. Clinical and hemodynamic improvement was also observed in the majority of the patients. This helped to discontinue PGE1 immediately in one third of our patients and within 8 h in the rest. This prevented the potential and

possible complications related to PGE1 administration. This also helped in the extubation of some of our patients who were on assisted ventilation, resulting in reduction in the cost of and in the duration of hospital stay. It has been reported<sup>[2]</sup> to be effective in infants below the age of two months, as the atrial septum is still thin and of low resistance. It has also been shown successful even up to the age of 6 months<sup>[11]</sup>. A word of caution should be exercised at this time, that an initial increase in oxygen saturation or clinical improvement does not guarantee long-term satisfactory results, and surgical intervention should be exercised as early as possible. This fact has been well documented by Baker *et al.*<sup>[12]</sup>.

### ***Echocardiographic/Fluoroscopic Monitoring of BAS***

Echocardiographic monitoring of BAS allows the procedure to be carried out in a more appropriate environment for the patient, at the bedside in the NICU or even away from the referral center with the same efficacy; thus, avoiding the risks of transferring a sick neonate to another hospital or another unit of the same hospital. Martin *et al.*<sup>[13]</sup> has recently assessed the advantages of transporting the specialized team to local neonatal ICU; to perform BAS under echocardiographic monitoring. It not only reduces the time preceding the procedure, but also has clinical, social and organizational advantages. Echocardiographic monitoring still remains a valuable tool in cases when the procedure is performed in the cardiac catheterization laboratory. It helps in measuring the size of interatrial communication, and the mobility of its margins. Lastly, the economic factor also has become important in medical practice. Zeller *et al.*<sup>[14]</sup> have shown that BAS at bedside is advantageous and reduces the cost of the procedure to half of that performed in the hemodynamic laboratory. This present study results have shown no difference between the echocardiographic or fluoroscopically monitored BAS in terms of the success and the efficacy of the procedure. Both the ASD size and the oxygen saturation increased after BAS in the patients as a whole, and also in both of the groups independently. Jamjureeruk *et al.*<sup>[11]</sup> and Marchi *et al.*<sup>[15]</sup> has also reported successful BAS under echocardiographic monitoring with the same results.

### ***Complications of BAS***

Though the procedure seems reasonable free of problems and complications, strict adherence to the technique yet, is required to avoid

infection and other potential complications. If BAS is performed under fluoroscopic guidance, then defining the balloon catheter in relation to the intra-cardiac structures could prove difficult. The risk of damage to the atrio-ventricular valves or cardiac perforation can be significantly reduced by the concomitant use of echocardiograph monitoring. The author encountered major complications only in 3 patients, while minor, transient and self-limiting complications were faced occasionally. The rate of complications is slightly more than what has already been published by Marchi and colleagues<sup>[15]</sup>. The supra-ventricular arrhythmias were reverted with the manipulation of the catheter inside the atria. The rupture of the balloon was related to the problems with the material and not directly related to the technique of the procedure. The risk of severe hypoxia, metabolic acidosis and possible death, due to poor mixing in sick patients, outweighs the rare report serious complications *e.g.*, cerebral embolism and cardiac tamponade. The two procedure related to deaths in our experience were due to the non-adherence precautions recommended for this procedure. The use of a stiff guide wire made the already stiff catheter, even stiffer, which lead to the perforation of the thin atrial wall in the first patient resulting in hemo-pericardium and cardiac tamponade. In the second case, advancing the catheter more than the recommended length (16 cm from the umbilicus) resulted in hepatic vein perforation, intra-peritoneal bleeding and death. This second mortality was potentially more preventable.

### Conclusions

BAS is a life saving procedure and can be performed at the bedside, under echocardiographic monitoring, and also in the catheterization laboratory with same success and efficacy. Echocardiographic monitoring is advantageous; being cost effective has organizational advantages and alleviates radiation exposure. Minor complications occur which are mostly self reversible. Major complications including mortality can occur, but these can be avoided if strict adherence to the technique is practiced, and echocardiographic monitoring is concomitantly used in the hemodynamic laboratory. If the facility for arterial switch operation exists, BAS can be avoided in patients with D-TGA. Moreover, surgical intervention can be done within 4-6 days, while the patient on PGE1. However, this does not undermine the benefits of BAS, as, and if required. Hence, the author believes that there should be low threshold

to perform BAS in D-TGA in patients who are hypoxemic, acidotic or in whom the surgical intervention is not possible within next 4-6 days.

#### References

- [1] **Matoos SS, Rodrigues JV, Severi R, Nunes M, Cunha CE, Melo VB, Didier LR, Gomes Kde F, Santos CL, Moraes CR.** [Management of tricuspid atresia in neonates. Report of three cases and review of literature] *J Pediatr (Rio J)* 1994; **70**(1): 33-38.
- [2] **Mullins CE, El-Said GM, Neches WH, Williams RL, Vargo TA, Nihill MR, McNamara DG.** Balloon atrial septostomy for total anomalous pulmonary venous return. *Br Heart J* 1973; **35**(7): 752-757.
- [3] **Shams A, Fowler RS, Trusler GA, Keith JD, Mustard WT.** Pulmonary atresia with intact ventricular septum: report of 50 cases. *Pediatrics* 1971; **47**(2): 370-377.
- [4] **Blalock A, Hanlon CR.** The surgical treatment of complete transposition of the aorta and the pulmonary artery. *Surg Gynecol Obstet* 1950; **90**(1): 1-15.
- [5] **Rashkind WJ, Miller WW.** Creation of atrial septal defect without thoracotomy. A palliative approach to complete transposition of the great arteries. *JAMA* 1966; **196**(11): 991-992.
- [6] **Perry LW, Galioto FM Jr, Blair T, Shapiro SR, Ruckman RN, Scott LP 3rd.** Two-dimensional echocardiography for catheter location and placement in infants and children. *Pediatrics* 1981; **67**(4): 541-547.
- [7] **Matsunaga S, Suzuki K, Ichinose E, Takeuchi S, Yoshioka F, Yokochi K, Tanaka C, Kato H.** Application of two dimensional echocardiography for the intracardiac manipulation: the evaluation of atrial septal movement before and after atrial septostomy. *J Cardiogr* 1981; **11**(1): 217-224.
- [8] **Allan LD, Leanage R, Wainwright R, Joseph MC, Tynan M.** Balloon atrial septostomy under two-dimensional echocardiographic control. *Br Heart J* 1982; **47**(1): 41-43.
- [9] **Perry LW, Ruckman RN, Galioto FM Jr, Shapiro SR, Potter BM, Scott LP 3rd.** Echocardiographically assisted balloon atrial septostomy. *Pediatrics* 1982; **70**(3): 403-408.
- [10] **Baker EJ, Allan LD, Tynan MJ, Jones OD, Joseph MC, Daverall PB.** Balloon atrial septostomy in the neonatal intensive care unit. *Br Heart J* 1984; **51**(4): 377-378.
- [11] **Jamjureeruk V, Sangtawesin C, Layangool T.** Balloon atrial septostomy under two-dimensional echocardiographic control: a new outlook. *Pediatr Cardiol* 1997; **18**(3): 197-200.
- [12] **Baker F, Baker L, Zoltun R, Zuberbuhler JR.** Effectiveness of Rashkind procedure in transposition of the great arteries in infants. *Circulation* 1971; **43**(5 Suppl): 1-6.
- [13] **Martin AC, Rigby ML, Penny DJ, Redington AN.** Bedside balloon atrial septostomy on neonatal units. *Arch Dis Child Fetal Neonatal Ed* 2003; **88**(4): F339-340.
- [14] **Zeller TM, Dixon K, Moake L, Wright J, Ramaciotti C.** Bedside balloon atrial septostomy is safe, efficacious, and cost effective compared with septostomy performed in cardiac catheterization laboratory. *Am J Cardiol* 2002; **89**(5): 613-615.
- [15] **Marchi CH, Godoy MF, Santos MA, Moscardini AC, Hassen Sobrinho S, Croti UA.** [Echocardiographic monitoring of balloon atrial septostomy] *Arq Bras Cardiol* 2005; **84**(3): 245-250.

## إحداث ثقب بين الأذنين في مرض انعكاس الشرايين القلبية العظمى

جميل عبدالعزيز العطا

قسم الأطفال، كلية الطب، جامعة الملك عبدالعزيز

جدة - المملكة العربية السعودية

المستخلص. نقدم تجربتنا في ثمانية عشرة عاما (من ١٩٨٧ - ٢٠٠٥م) في استخدام قثطرة بالبالون. لإحداث ثقب في الحاجز بين الأذنين في انعكاس الشرايين العظمى للقلب. تم علاج أربعة وأربعين مريضاً بهذه التقنية كما تم تقسيمهم لمجموعتين (المجموعة أ - ١٩ مريض) بالأشعة الصوتية للقلب، و(المجموعة ب - ٢٥ مريض) بالأشعة السينية. بمقارنة الثقب بين الأذنين وتركيز الأكسجين في المجموعتين قبل وبعد القثطرة. وجد أن الثقب زاد من (٢,٣ ± ٠,٦ ملم) إلى (٤,٩ ± ١,٣ ملم) وزاد أيضا تركيز الأكسجين من (٤٨ ± ٨٪) إلى (٧٢ ± ١٦,٣٪) في كلا المجموعتين بزيادة معتبرة إحصائياً. وزاد كلا المتغيران استقلالياً بقيم إحصائية معتبرة. ولوحظ اضطراب في ضربات القلب في ٣ مرضى بينما انفجر بالون القثطرة في حالة، ولكن دون مضاعفات وقد أصيب مريض بهبوط في التنفس (بسبب المورفين) احتاج لتنفس صناعي مؤقت. توفيت حالتان إحداهما بسبب تجمع سوائل حول القلب، والأخرى نتيجة ثقب الوريد الكبدى. وتوفيت حالتان بسبب حموضة مستمرة في الدم حتى بعد نجاح القثطرة (بسبب تأخر الوصول للمستشفى). وقد خلصنا إلى أن التقنية آمنة وفعالة



وتتقد الحياة حتى إجراء الجراحة. وهي فعالة بالأشعة فوق الصوتية  
أو بالأشعة السينية.