

## **Epidermolysis Bullosa: Experience from the Western Province of Saudi Arabia**

Sawsan M. Jalalah\*, MB BCH, PhD, Ali S. Sawan, MD, PhD,  
and Sameer K. Zimmo, MD\*

*Department of Pathology, \*Dermatology Division, Faculty of Medicine,  
King Abdulaziz University, Jeddah, Saudi Arabia  
sjalalah@hotmail.com*

*Abstract.* Epidermolysis bullosa is a rare inherited bullous disease with unknown prevalence in most parts of the world. In Saudi Arabia the reported studies regarding epidermolysis bullosa are very limited. This paper presents the first study of epidermolysis bullosa cases from the Western province of Saudi Arabia. We studied 15 cases of inherited epidermolysis bullosa and classified the cases based on electron microscopic studies into the three basic types of epidermolysis bullosa. These results demonstrated that the most common type of epidermolysis bullosa in the cases studied is junctional epidermolysis bullosa, in contrast to previous reports where epidermolysis bullosa simplex and dystrophic epidermolysis bullosa are more common than junctional epidermolysis bullosa. These results reveal the need for a larger epidermolysis bullosa study in this part of the world.

*Keywords:* Epidermolysis bullosa, Simplex, Dystrophic, Junctional, Saudi Arabia.

### **Introduction**

Epidermolysis bullosa (EB) is a group of inherited bullous disorders of the epithelial basement membrane zone; that is characterized by blister formation in the skin and mucous membranes in response to trauma. Major types of EB

---

\*To whom all correspondence & reprint requests: P.O. Box 80215, Jeddah 21589 Saudi Arabia.  
Accepted for publication: 07 March 2006. Received: 16 May 2005.

include EB simplex (EBS), junctional EB (EBJ) and dystrophic EB (DEB). The classification of EB depends mainly on ultrastructural studies to evaluate the level of the cleavage and the site of bullous formation. The specific planes of blister formation result from structural and molecular defects of major target proteins in the three types of EB. Recent molecular genetic studies have revealed abnormalities in specific proteins for most EB types. EBS shows intraepidermal cleavage and molecular defect in the keratin molecule, EBJ is characterized by blistering at the level of *lamina lucida* and molecular defect in the laminin chains, in the third type, DEB. The cleavage plane is at the sublamina densa and the molecular defect affects Type VII collagen<sup>[1, 2]</sup>.

Few studies of inherited EB are reported in literature from diverse areas of the world<sup>[3,4]</sup>. Although some of these reports are not formal epidemiological surveys, their results contributed to the understanding of the disease and its worldwide distribution. In this respect, little data has been published from the Middle East area including Saudi Arabia<sup>[5-10]</sup>.

In this study, we report our experience with EB cases in the western province of Saudi Arabia over a period of sixteen years, to add to the compiling reports from this region of the world in the hope that this will lead to a better understanding of the disease in our area.

### **Material and Methods**

This is a retrospective study of EB cases. The study consisted of 17 EB patients clinically diagnosed as inherited EB in the period between 1988 and 2004. Patients were referred from the dermatology clinic at King Abdulaziz University Hospital (KAUH), or were referred cases from different hospitals in the Western province. Out of these 17 cases only 15 cases were examined by light and electron microscopic studies, while the skin biopsy was inadequate for diagnosis in the remaining 2 cases.

A punch skin biopsy of a fresh mechanically induced blister was obtained from the patients. The skin tissue was divided for light microscopy and electron microscopy studies in the Pathology Department at KAUH.

For the purpose of light microscopy studies, the skin biopsy was processed into paraffin blocks following the routine tissue processing schedule in the pathology laboratories. The consultant pathologists examined the tissue sections stained with Hematoxylin and Eosin (H&E) and Periodic Acid Schiff (PAS).

For transmission electron microscopy studies fresh skin tissue was submitted at the time of the biopsy from all the cases in this retrospective study. Examination of biopsies from EB cases by the transmission electron microscope is the

gold standard to determine the level of cleavage; hence electron microscopy plays a major role in the classification of the different types of EB<sup>[1]</sup>.

The tissue was processed into plastic blocks following the routine tissue processing methods for transmission electron microscope. Skin tissue, cut into 2 mm<sup>3</sup> pieces, was fixed in 4% glutaraldehyde fixative in cacodylate buffer, followed by postfixation in 2% buffered osmium tetroxide. Tissue was then dehydrated in graded ethanol, processed through propylene oxide and embedded in Epon resin. Polymerization of tissue blocks was done in 60°C oven. Ultrathin sections stained with uranyl acetate and lead citrate were examined under the Phillips CM100 transmission electron microscope. All cases were studied by the electron microscopist consultant.

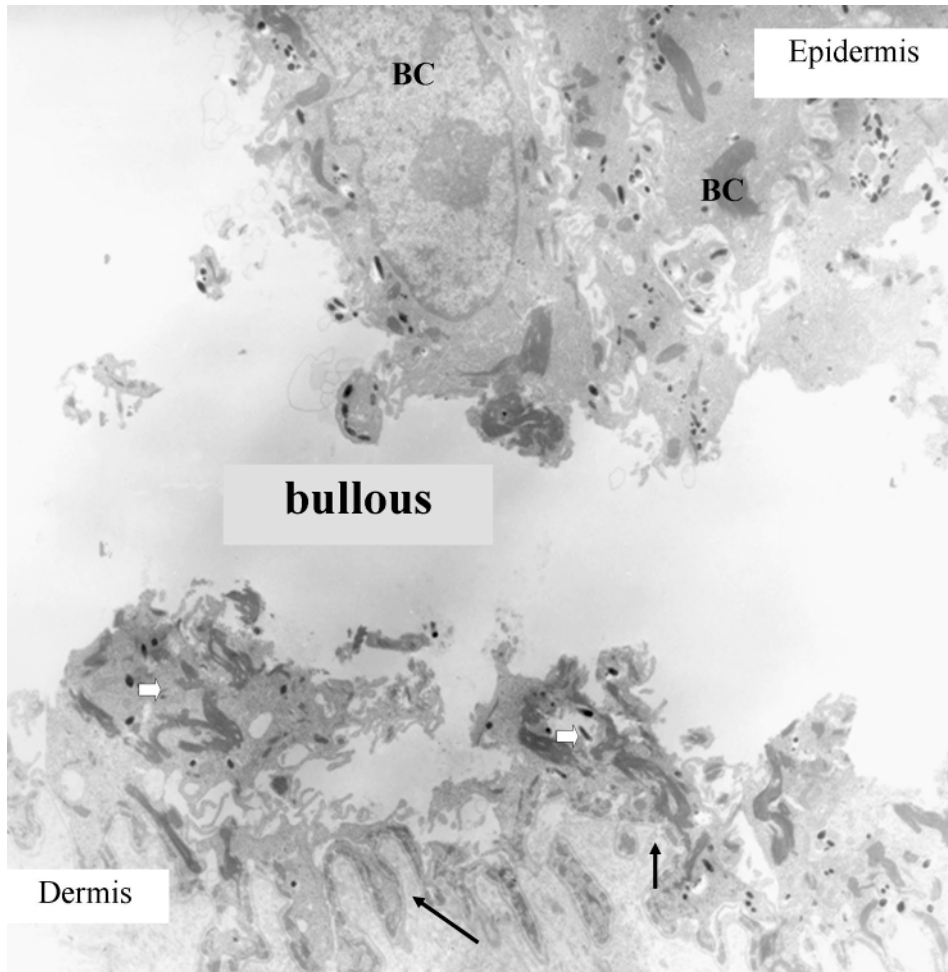
## Results

Histological analysis of H&E and PAS stained sections of EB cases in this study demonstrated intraepidermal separation and bullous formation in the two cases of EBS, the basal lamina stained with PAS is observed at the bottom of the bullous. Cases of the other two types (EBJ and DEB) showed the bullous formation at the subepidermal level, distinction between these two types is difficult even with the PAS stain.

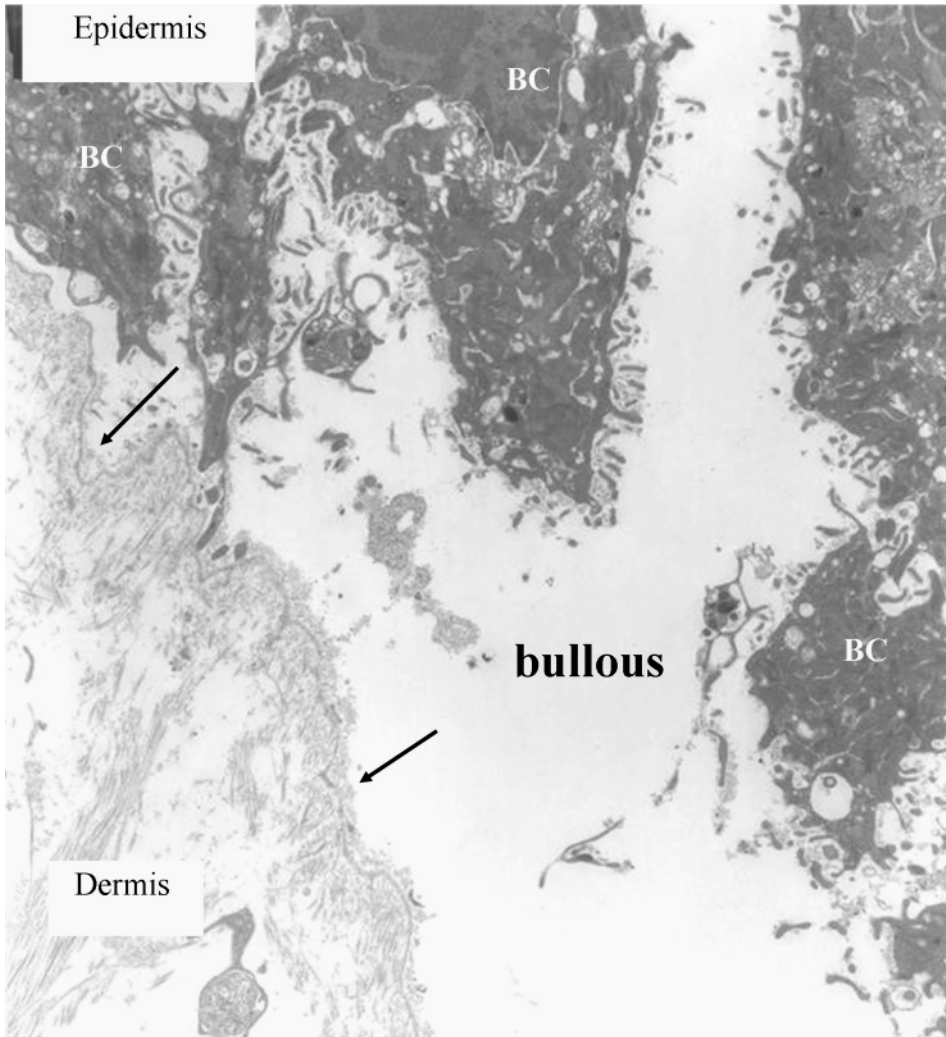
Histological study of skin biopsy is insufficient to classify EB<sup>[2]</sup>, thus this study's cases are classified and grouped into the three major types of EB using mainly electron microscopy studies (Table 1). Following the ultrastructural criteria for the classification of EB, as established by “the revised classification system for inherited EB”<sup>[1]</sup>, our EB cases are classified into the three major types of EB, as follows: 1) EBS “epidermolytic EB” (Fig. 1) where the cleavage occurs across the cytoplasm of the basal cell layer and 2) (EBJ) where the bullous is formed intraepidermally; (Fig. 2) the separation takes place between the cell membrane of basal cell layer and the lamina lucida of basement membrane; and 3) DEB “dermolytic EB” (Fig. 3) where the cleavage is detected at the sublamina densa level of the basement membrane.

**Table 1. Percentages of the different types of epidermolysis bullosa in the cases studied.**

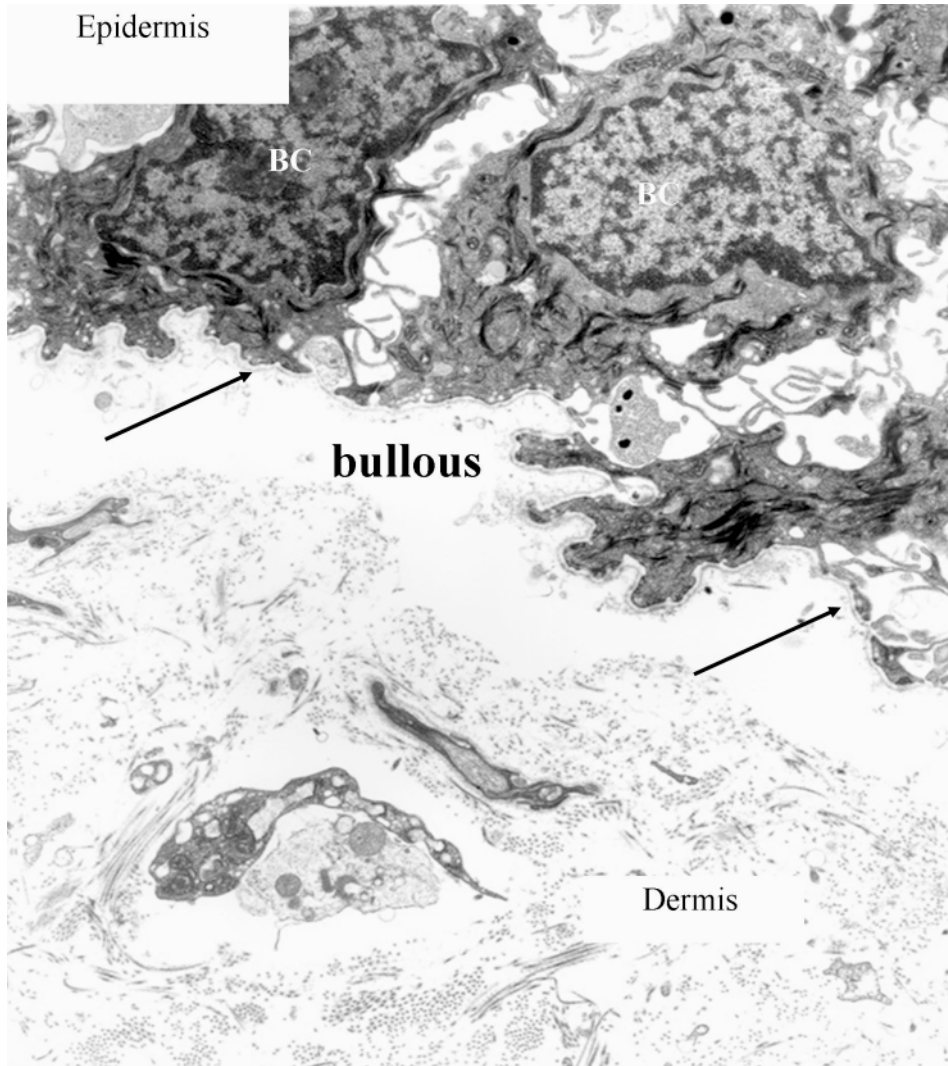
EB Type	Number of Cases (n=15)	Percentage (%)	Sex of Patient		Age Range
			Males (n=7)	Females (n=8)	
Junctional EB	8	53.3 %	(4)	(4)	13 days - 3 month
Dystrophic EB	5	33.3 %	(1)	(4)	1 month - 9 month
EB Simplex	2	13.3 %	(2)	(0)	3 month - 8 month



**Fig. 1. EB Simplex (EBS):** Electron micrograph showing the cleavage line across the cytoplasm of the basal cells (BC). The bullous is formed in the epidermis. Fragments of the basal cells (white thick arrows) together with the basement membrane (black arrows) are detached with the dermal layer forming the bottom of the bullous; and the remaining fragments of the basal cells cytoplasm of epidermis form the roof of the bullous.



**Fig. 2. Junctional (JEB):** Electron micrograph demonstrating the cleavage line at the level of the lamina lucida of basement membrane (black arrows), forming the bullous. The roof of the bullous is lined by the plasma membrane of the basal cell layer (BC) of the epidermis; and the bottom is lined by the basement membrane attached to dermis.



**Fig. 3. Dystrophic EB (DEB):** Electron micrograph demonstrating the cleavage line in sublamina densa of basement membrane. The bullous is formed between the epidermis and dermis. It is lined by the basement membrane (black arrows) at the top of the bullous attached to the basal cells (BC) of the epidermis, and the bottom of the bullous is lined by the dermis.

The percentages of each EB type in our cases were determined (Table 1). Eight cases were diagnosed as EBJ (4 males and 4 females) out of the total 15 studied EB cases representing 53.3%. The DEB cases represent 33.3% out of the total EB cases studied; five cases were diagnosed as DEB (one male and 4 females).

EBS was diagnosed in 2 males out of the 15 EB cases studied; occurrence rate represents 13.3%.

## Discussion

EB is a rare inherited blistering disorder. Reports of EB cases have been accumulated from different parts of the world, however, few of these reports are the result of well organized epidemiological studies and national registries<sup>[3-4]</sup>.

The prevalence of EB in Saudi Arabia has not yet been determined. To our knowledge, there is one report from the Eastern province of Saudi Arabia<sup>[7]</sup>; however, there are no reports of EB cases from the Western province in previous literature.

In this study we report our experience with EB cases from KAUH and cases referred from other hospitals in the Western province.

Most of the patients in this report are suffering from EBJ (53%), and the least frequent diagnosis is EBS (13.3%). This observation is in disagreement to those previously in which EBJ was found to be the least diagnosed entity among EB cases<sup>[3,4,7,10]</sup>. In some series the EBS was the most common type as reported in studies from Norway, Northern Ireland, Finland and Japan. Whereas reports from Croatia and South Africa indicated that DEB was the most common type. Similarly, the EB study of sixteen cases from the Eastern province of Saudi Arabia also demonstrated DEB as the most commonly occurring type (62.5%). Strikingly, in contrast to this study's results, there were no cases of the EBJ type reported in the Eastern Province study<sup>[7]</sup>.

This study reveals the need for further studies of EB cases from this region of the world to establish the EB phenotypes and genotypes in our patients.. In support of this, there is evidence in the literature indicating that gene mutations found in cases of EB in the Middle East are different from those found in other parts of the world<sup>[5]</sup>. Reports from the United States show 50% of the mutations in EBJ to be LAMB3 (R635X and R42X) mutations<sup>[11,12]</sup>. In contrast, Nakano *et al.* studied the genetic defects in Middle Eastern patients diagnosed with EBJ; their results indicated that an equal number of cases were found to have mutations in the three chains of laminin-5, LAMB3, LAMA3 AND LAMC2. In addition they reported that the mutation detected in LAMB3 was (Q1083X) and

none of the mutations of LAMB3 were (R635X and R42X)<sup>[5]</sup>. Another research group reported the same type of LAMB3 mutation (Q1083X) in EBJ in a Lebanese family<sup>[8]</sup>. These studies suggest the existence of a specific spectrum of EB mutations in the Middle East population which could be related to consanguinity.

Accordingly the predominance of EBJ cases in this study might be the result of consanguinity which has lead to a specific type of gene mutation in this part of the world. However this is a retrospective study and due to lack of demographic information on these patients the assumption of consanguinity as a reason for the increased frequency of EBJ can not be confirmed.

The 17 EB cases concerned in this study over the sixteen year period probably do not reflect the actual frequency of EB cases in our region. However, the reporting of these EB cases contributes to the understanding of EB in the region. The study established that in contrast to the findings reported in previous literature the most common EB cases observed belong to EBJ. These results prove the need for larger scale studies of EB in order to achieve a better understanding of this disease. Moreover, such studies would assist in establishing a national EB registry in the Kingdom of Saudi Arabia.

### References

- [1] **Fine JD, Eady RA, Bauer EA, Briggaman RA, Bruckner-Tuderman L, Christiano A, Heagerty A, Hintner H, Jonkman MF, McGrath J, McGuire J, Moshell A, Shimizu H, Tadini G, Uitto J.** Revised classification system for inherited epidermolysis bullosa: Report of the Second International Consensus Meeting on diagnosis and classification of epidermolysis bullosa. *J Am Acad Dermatol* 2000; **42**(6): 1051-1066.
- [2] **Pai S, Marinkovich MP.** Epidermolysis bullosa: New and emerging trends. *Am J Clin Dermatol* 2002; **3**(60): 371-380.
- [3] **Horn HM, Priestley GC, Eady RA, Tidman MJ.** The prevalence of epidermolysis bullosa in Scotland. *Br J Dermatol* 1997; **136**(4): 560-564.
- [4] **McKenna KE, Walsh MY, Bingham EA.** Epidermolysis bullosa in Northern Ireland. *Br J Dermatol* 1992; **127**(4): 318-321.
- [5] **Nakano A, Lestringant GG, Paperna T, Bergman R, Gershoni R, Frossard P, Kanaan M, Meneguzzi G, Richard G, Pfindner E, Uitto J, Pulkkinen L, Sprecher E.** Junctional epidermolysis bullosa in the Middle East: Clinical and genetic studies in a series of consanguineous families. *J Am Acad Dermatol* 2002; **46**(4): 510-516.
- [6] **Abahussein AA, Al-Zayir AA, Mostafa WZ, Okoro AN.** Recessive dystrophic epidermolysis bullosa treated with phenytoin. *Int J Dermatol* 1992; **31**(10): 730-732.
- [7] **Abahussein AA, Al-Zayir AA, Mostafa WZ, Okoro AN.** Epidermolysis bullosa in the Eastern province of Saudi Arabia. *In J Dermatol* 1993; **32**(8): 579-581.
- [8] **Ayoub N, Tomb R, Charlesworth A, Meneguzzi G.** Junctional epidermolysis bullosa. Identification of a new mutation in two Lebanese families. *Ann Dermatol Venereol* 2005; **132**(6-7 Pt 1): 550-553.



- [9] **Hacham-Zadeh S, Rappersberger K, Livshin R, Konrad K.** Epidermolysis bullosa herpetiformis Dowling-Meara in a large family. *J Am Acad Dermatol* 1988; **18**(4 Pt 1): 702-706.
- [10] **Fine JD.** Epidermolysis bullosa. Application of epidemiologic principles to the study of a group of rare disease via a disease registry. *Dermatol Clinics* 1995; **13**(3): 659-670.
- [11] **Nakano A, Pfindner E, Hashimoto I, Uitto J.** Herlitz junctional epidermolysis bullosa: Novel and recurrent mutations in LAMB3 gene and the population carrier frequency. *J Invest Dermatol* 2000; **115**(13): 493-498.
- [12] **Pulkkinen L, Uitto J, Christiano AM.** The molecular basis of the junctional forms of epidermolysis bullosa. In: *Epidermolysis Bullosa*, Ed. JD Fine, *et al.* Baltimore: John Hopkins U P, 1999. 300-325.

## انحلال البشرة الفقاعي: دراسة من المنطقة الغربية في المملكة العربية السعودية

سوسن محمد جلله ، و علي صادق صوان ، و سمير خضر زمو\*  
قسم علم الأمراض و \*شعبة الأمراض الجلدية ، كلية الطب  
جامعة الملك عبدالعزيز ، جدة - المملكة العربية السعودية

المستخلص. انحلال البشرة الفقاعي يعتبر من الأمراض الوراثية النادرة، ونسبة حدوثه في أغلب مناطق العالم غير معروفة. الدراسات المنشورة عن هذا المرض في المملكة العربية السعودية قليلة جداً. دراستنا الحالية تقدم أول تقرير عن هذا المرض في المنطقة الغربية للمملكة. تحتوي دراستنا على ١٥ حالة من هذا المرض ، وتم تقسيمهم بناء على نتيجة الفحص باستخدام المجهر الإلكتروني إلى الثلاثة أصناف الرئيسية لمرض انحلال البشرة الفقاعي. نتائج دراستنا أثبتت أن أكثر الأصناف حدوثاً بين الحالات التي دُرست هو الصنف المسمى انحلال البشرة الفقاعي الالتحامي، و ذلك على عكس نتائج الدراسات السابقة والتي أوردت أن أكثر الأصناف شيوعاً هو انحلال البشرة الفقاعي السفلي. نتائج هذه الدراسة تشير إلى الحاجة لدراسة أشمل عن مرض انحلال البشرة الفقاعي في هذه المنطقة من العالم.