

## Hamate Bone Dislocation: A Case Report

BASIM A. AWAN, FRCS<sup>\*</sup>, G. A. ROBERTSON, FRCS, FRCS<sup>\*\*</sup>

*\*Department of Surgery, Faculty of Medicine & Allied Sciences,  
King Abdulaziz University, Jeddah, Saudi Arabia,*

*\*\*Division of Plastic and Reconstructive Surgery, Health Sciences Center,  
University of Manitoba, Winnipeg, Manitoba, Canada*

**ABSTRACT.** A case of hamate dislocation is presented. This is associated with subluxation of the fourth and fifth metacarpal bones with the hamate in a dorsal direction. No other carpal or metacarpus injury was involved. The mechanism of injury was a direct crushing force. A close reduction was attempted successfully with percutaneous K-wire fixation. These were removed after 6 weeks and physiotherapy continued for another 6 weeks. The patient was able to return to his normal work with near normal hand function.

**Keywords:** Hamate, Hamate dislocation, Carpal dislocation.

### Introduction

Dislocation of the hamate is an extremely rare injury, with only 19 cases being reported since Buchanan described a "luxation of the unciform bone" in 1982<sup>[1]</sup>. This study describes a case report and reviews the previously reported cases outlining the proper management.

### Case Report

A 34-year old man sustained a crush injury of his nondominant left hand that had been caught laterally between a hydraulic splinter and log. He was seen in the Emergency Department with a swollen left hand and a 3 cm laceration at the first web space

---

Correspondence & reprint requests to: Dr. Basim Awan, P.O. Box 80215, Jeddah 21589, Saudi Arabia.  
Accepted for Publication: 21 June 1999. Received: 8 February 1999.

with a macerated muscle mass protruding through. There was no evidence of neurological or vascular injuries to the hand. He is otherwise healthy. Radiological examination revealed a dislocation of the Hamate bone in a dorsal direction with the fourth radiological examination revealing a dislocation of the hamate bone in a dorsal direction with the fourth and fifth metacarpals having moved with the hamate (Figure 1, Plates A & B). There were no fractures.

The wound in the first web was irrigated and closed temporarily in the Emergency room. Later the patient was taken to the operating room and under regional anesthesia with tourniquet a closed reduction of the dislocated hamate with the fourth and fifth metacarpals was achieved under control of an image intensifier immobilized with two percutaneous K-wires. One K-wire was passed through the reduced hamate into the capitate and the other through the bases of the fifth to second metacarpal bones (Figure 1, Plates C, D, E, F, G).

The wound in the first web space was re-explored. The macerated muscle was the bulk of the adductor pollicis, which had been avulsed from its origin and was not repairable. Minimal debridement was done for the muscle and pushed inside the wound which was closed over. A volar slab was incorporated in the dressing and intravenous antibiotics were given with elevation of the hand. The patient was observed with frequent assessment for the development of compartment syndrome for 3 days during which most of the swelling was resolved. A splint was applied afterwards and the patient was discharged from the hospital with a follow-up appointment after 1 week. He was instructed for elevation of the hand and active exercise of the fingers while the wrist was immobilized in the splint.

The K-wires were removed after 6 weeks and physiotherapy begun for active and then passive ROM of the wrist. Six weeks after therapy, he had recovered a full ROM at both wrist and MCP joints. Good cupping and a stable transverse metacarpal arch on grip showed that he had maintained the integrity of the ulnar-rotating column. There was occasional pain on the ulnar side of the wrist with a strong grip. Radiological examination with a wide range of movements showed no instability patterns (Figure 2, Plates A, B, C, D, E). Three months after surgery the patient was able to return to work with no subsequent major complaint.

### Discussion

Isolated dislocation of the hamate bone may be volar or dorsal. Gunn<sup>[2]</sup> reported 5 volar, 3 dorsal and 3 unknown. Thereafter the 5 reported cases were 2 volar and 3 dorsal, including this case.

The mechanism of injury in most of the cases (8 cases including this case) was a direct impact, while an indirect trauma was reported to be the cause in 4 cases, the mechanism was unknown in another 4 reported cases.

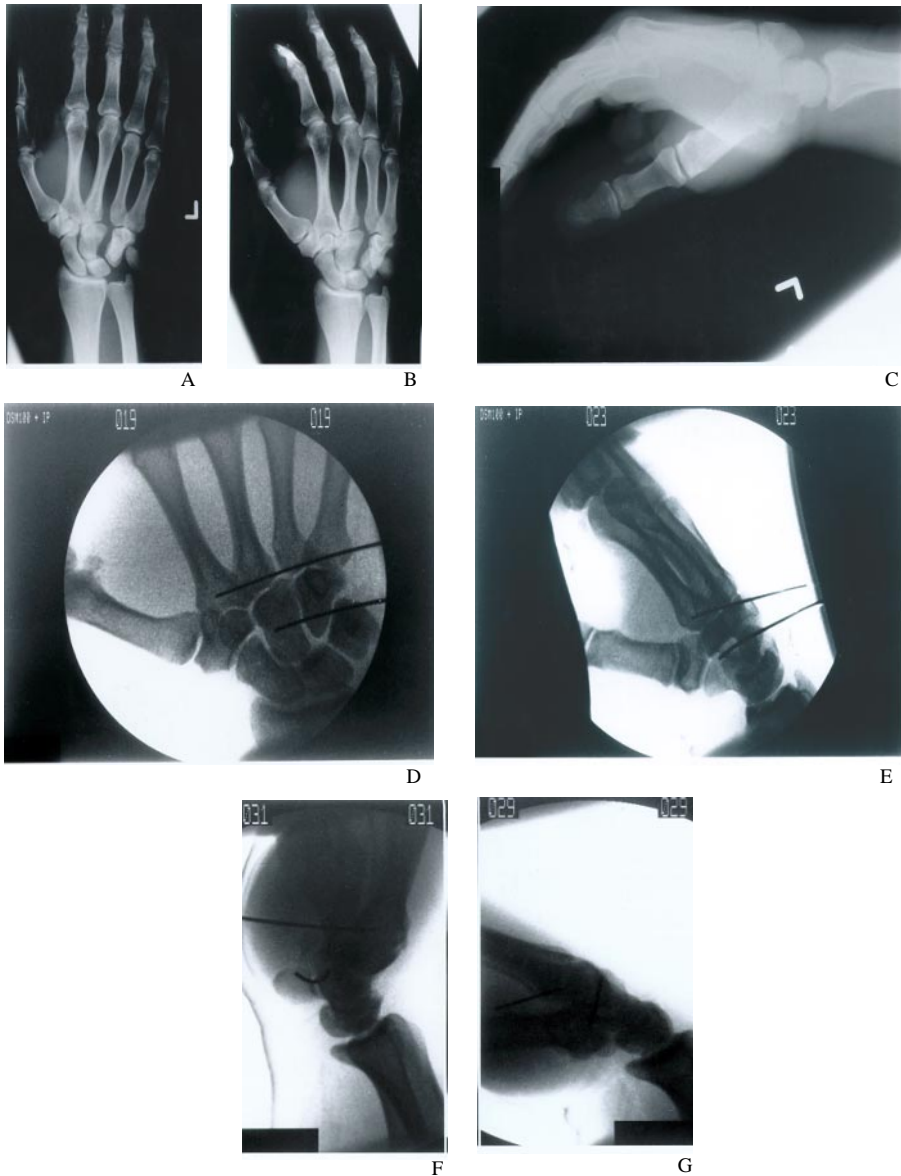


Fig. 1. Plate A & B: A-P and oblique views show the dorsal dislocation of the hamate bone associated with the fourth and fifth metacarpals. Notice the space between the capitate and the triquetral bones and the widening between the third and fourth metacarpal bases. Plate C: Lateral view shows the dorsal dislocation of the hamate with the fourth and fifth metacarpals. Plate D: A-P view after closed reduction and percutaneous K-wire fixation. Notice the anatomical reduction. Plate E: Lateral view post-closed reduction and K-wire fixation. Plate F & G: Lateral views post-reduction in hyperextension and hyperflexion of the wrist. Notice the stability of the reduction.

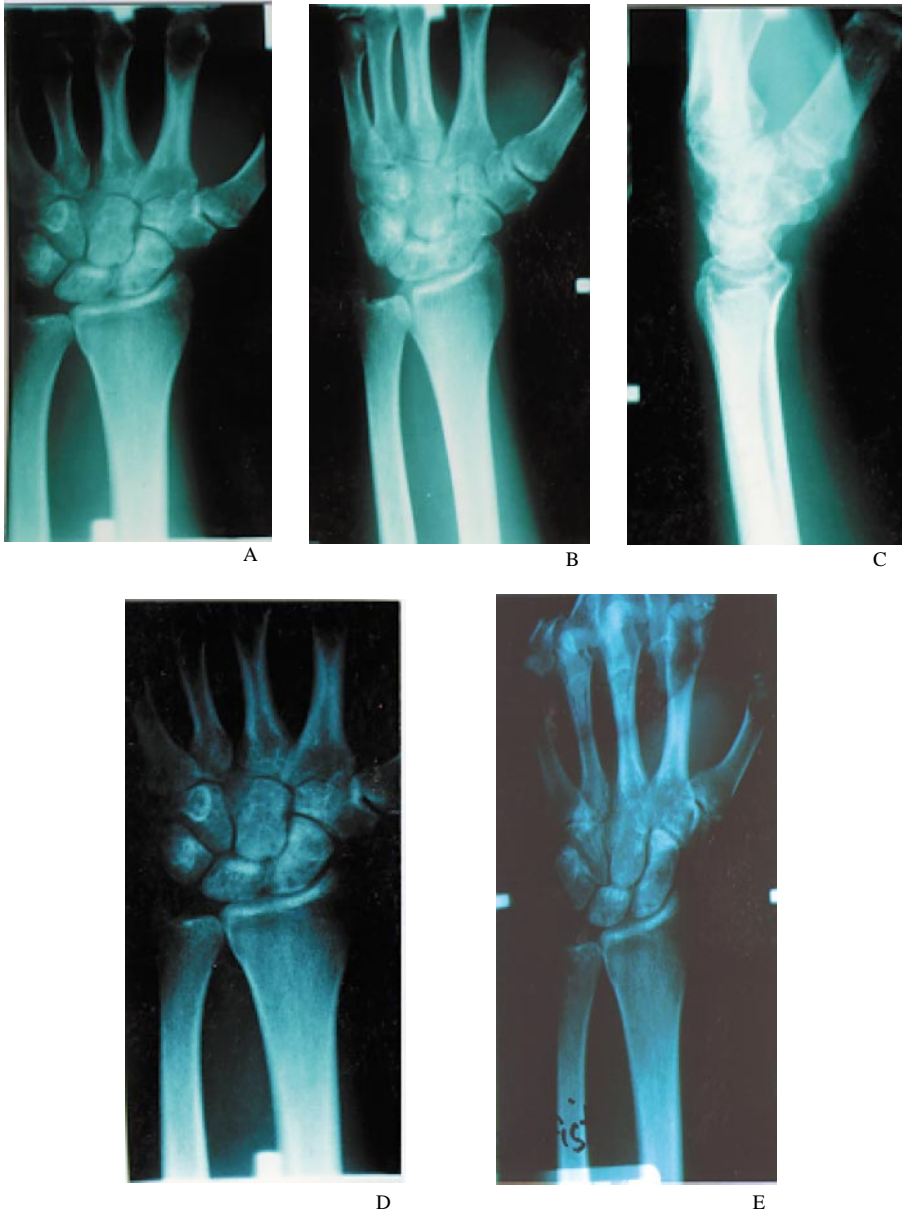

Fig. 2. Plate A: A-P view. Plate B: Oblique and lateral views. Plate C: 3 months post reduction. Plate D & E: Stability of the reduction with forceful closed fist.

The physical signs usually include painful swelling of the hand, which is worse on the ulnar side with limitation of movement.

A definitive treatment was reported only for 13 cases. One case was treated conservatively with poor results<sup>[2]</sup>. 3 cases (all volar dislocation) treated successfully by closed reduction<sup>[3,4]</sup>. One of them had no follow-up, while the other 2 cases with a follow-up of 10 months and 12 years showed a mild degree of limited extension on the extreme of function. Four cases were treated by excision of the hamate with good results<sup>[2]</sup>. Two cases (volar & dorsal) were treated primarily by ORIF and cast for 6 weeks<sup>[5,2]</sup>, both had good results. Two other cases (dorsal & volar) had unsuccessful attempts of closed reduction<sup>[6,7]</sup>, therefore, treated by open reduction. The former was treated without fixation, but cast for 4 weeks and the later one was fixed with k-wire and cast for 5 weeks. Both cases had a good result after 4 & 10 months of follow-up.

Our patient caught his hand between a hydraulic splinter and log, which caused the hamate bone with the fourth and fifth metacarpal bones to dislocate dorsally as one unit. This proves the presence of a weak point at the capito-hamate and triquetro-hamate joints, with the possibilities of tearing the dorsal carpal ligaments across these two joints.

With such grate compressive force injury, the transverse carpal ligament could be injured which did not happen in this patient since the x-ray did not show fracture of the hook of the hamate. Also, the successful attempt of close reduction was without difficulty and the patient never complained of volar wrist pain (as in pillar pain) during the follow-up period and all of these suggest an intact transverse carpal ligament.

The postoperative pain on the dorsal ulnar area of the wrist that the patient complained of after making a strong grip or after a heavy workload could suggest the need to reconstruct the dorsal carpal ligament. However, the patient returned to work and never came back for further follow-up.

In conclusion, dislocation of the hamate bone is rare. It usually occurs following moderate to severe direct impact, as indicated with the mechanism of injury and the associated soft tissue injury and some bony fracture, although it may occur with indirect violence as indicated by Johansson, 1926<sup>[8]</sup>. Volar dislocation is slightly more common than dorsal dislocation. The ulnar metacarpal rays usually dislocate with the hamate as one unit. Closed reduction should always be attempted as a prime mode of treatment with or without k-wire fixation. Open reduction should be the alternative method. Immobilization for 4-6 weeks is indicated. Either method, if successfully attempted, gives good results.

#### References

- [1] **Buchanan JG.** Luxation of the Unciform Bone. *Med and Surg Reporter* 1982; **XLVI**: 418.

- [2] **Gunn RS.** Dislocation of the hamate bone. *J Hand Surg [Br]* 1985; **10(1)**: 107-108.
- [3] **Duke R.** Dislocation of the hamate bone. *J Bone Joint Surg [Br]* 1963; **45-B**: 744.
- [4] **Garcia-Elias M, Abanco J, Salvador E, Sanchez R.** Crush injury of the carpus. *J Bone Joint Surg [Br]* 1985; **67(2)**: 286-289.
- [5] **Gainor BJ.** Simultaneous dislocation of the hamate and pisiform: A Case Report. *J Hand Surg [Am]* 1985; **10(1)**: 88-90.
- [6] **Geist DC.** Dislocation of the hamate bone, Report of a case. *J Bone Joint Surg* 1939; **21(1)**: 215-217.
- [7] **Ohshio I, Toshiko O, Miyake A.** Dislocation of the hamate associated with fracture of the trapezium ridge. *J Hand Surgery [Am]* 1986; **11(5)**: 658-660.
- [8] **Johansson Sven.** Ein fall von luxation des os hamatum. *Acta Radiologica* 1926; **7**: 9-13.

## انفصال العظم المحجني

باسم عبدالله عوان\* وج. آ. روبرتسون\*\*  
 \*قسم الجراحة، كلية الطب والعلوم الطبية، جامعة الملك عبدالعزيز،  
 جدة - المملكة العربية السعودية  
 و\*\*قسم جراحة التجميل وإعادة البنية، مركز العلوم الصحية،  
 جامعة مانيتوبا ويننج، مانيتوبا - كندا

المستخلص. نستعرض حالة انفصال العظم المحجني "العظم الشصي" مصحوبة بانفصال في العظام المشطية الرابعة والخامسة من اليد في الاتجاه الكفي، وغير مصحوبة بأي إصابات أخرى في العظام الرسغية أو المشطية الأخرى في اليد. آلية الإصابة هي قوة ضاغطة مباشرة. تم العلاج بطريقة الإرجاع المغلق مع التثبيت بمسامير كيرشنر التي تم إدخالها من خلال الجلد. تم إزالة المثبطات بعد ستة أسابيع وتبع ذلك استكمال العلاج الطبيعي لمدة ستة أسابيع أخرى، رجع بعدها المريض إلى عمله السابق واستخدم يديه دون مضاعفات.