

The Spectrum of Congenital Heart Diseases in Robinow Syndrome

JAMEEL AL-ATA, FRCP(C)*, MARC PAQUET, FRCP(C)*,
and AHMED S. AL-TEEBI, FRCP(ED)**

Division of Pediatric Cardiology and Division of Medical Genetics**,
The Montreal Children's Hospital, Montreal, Quebec, Canada*

ABSTRACT. We present the case of a newborn infant with classical signs of Robinow Syndrome and major congenital cardiac malformations consisting of double outlet right ventricle with subaortic VSD, infundibular and valvular stenosis, and patent ductus arteriosus. Similar patients of Robinow Syndrome with cardiac involvement are briefly reviewed from the literature and the importance of recognizing heart defects in early life is stressed.

Keywords: Right ventricle, Robinow Syndrome, Congenital, Patent ductus arteriosus, Ventricular septal defect, Pulmonary atresia, Double outlet, Right ventricle, Autosomal inheritance.

Introduction

Robinow Syndrome is a rare genetic disorder associated with fetal face appearance and genital hypoplasia with or without limb shortness. It exists as both autosomal dominant and autosomal recessive forms [1,2]. Cardiac malformations have been described in patients with Robinow Syndrome [3], but no specific pattern has been identified. Previously reported cases include ASD [4], Tetralogy of Fallot [5], coarctation of the aorta and bicuspid aortic valve [6], severe valvular pulmonary stenosis with VSO [7], pulmonary atresia with intact ventricular septum, isolated POA [8], and tricuspid atresia [3]. In the present report we describe a case of Robinow Syndrome with associated double outlet right ventricle (DORV), subaortic VSD, infundibular and valvular pulmonary stenosis, and a POA. Such cardiac anomaly has not been recognized before in patients with Robinow Syndrome.

Correspondence & reprint requests to: Dr. J. Al-Ata, Division of Pediatric Cardiology, Room C-352, The Montreal Children's Hospital, 2300 Tupper Street, Montreal, Que H3H 1P3, Canada.

Accepted for publication: 23 February 1998. Received: 07 October 1997.

Case report: The patient was a male infant born at full term to a healthy GZpoA1 mother by spontaneous vaginal delivery. He was noted to have dysmorphic features and cyanosis with minimal respiratory distress in the first few hours of life. His parents were phenotypically normal and were of southeastern Asian origin. They were non-consanguineous and their family history was unremarkable. Examination showed a relatively large head with frontal bossing and fetal face appearance, wide palpebral fissures and prominent eyes, depressed nasal bridge with short nose, anteverted nares and long philtrum, triangular mouth with thick alveolar ridge and narrow palate, posteriorly angulated ears and fleshy ear lobules. Both upper and lower extremities were relatively short with a meso-rhizemic appearance (Fig. I). His penis and scrotum were under-developed.

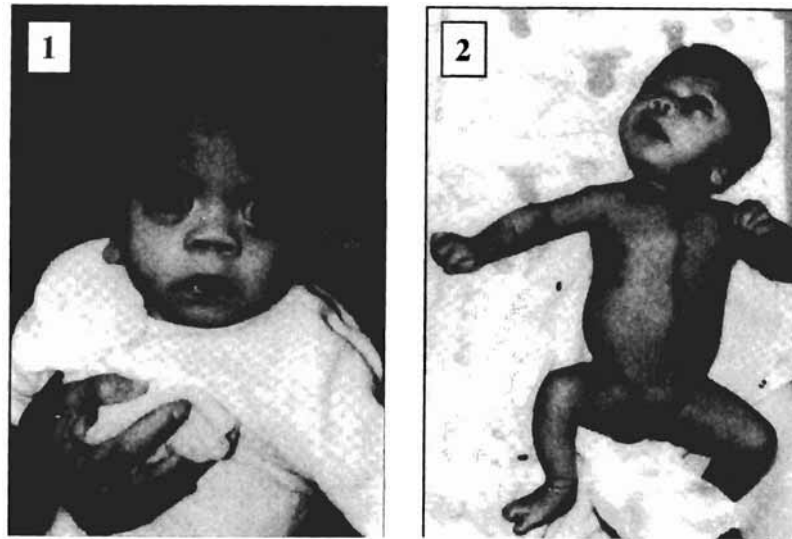


FIG. I. Plate I: Photograph of the patient demonstrating typical fetal face appearance with frontal bossing and prominent eyes.

Plate Z: Note relatively short upper and lower limbs and the under-developed external genitalia (the midline sternotomy scar is also noted).

Cardiovascular examination revealed (HR 120 BPM, BP 68/44 mmHg) equal yet slightly weak pulses in all four limbs, a hyperactive RV impulse, and thrill in the left upper sternal border. Auscultation revealed a normal S1, a single loud S2, and a grade 4/6 harsh ejection systolic murmur heart with maximal intensity at 2nd left intercostal space near the sternal border; diastole was clear. The chest was clear to auscultation and no organomegaly was detected on abdominal examination. The chest x-ray revealed abdominal situs solitus, levo-cardiac with boot-shaped cardiac silhouette left aortic arch and small lung volumes. The electrocardiogram showed sinus rhythm, absence of normal R-wave transition on the precordial leads with absent Q-wave in V6 suggesting right ventricular hypertrophy. Two-dimensional echocardiography revealed atrial situs

solitus, normal systemic and pulmonary venous drainage, secundum atrial septal defect. DORV with single anterior malalignment ventricular septal defect, severe infundibular and valvular pulmonary stenosis, proximal left pulmonary artery stenosis and a PDA (Fig. 2). Right and left cardiac cauterization confirmed the diagnosis.

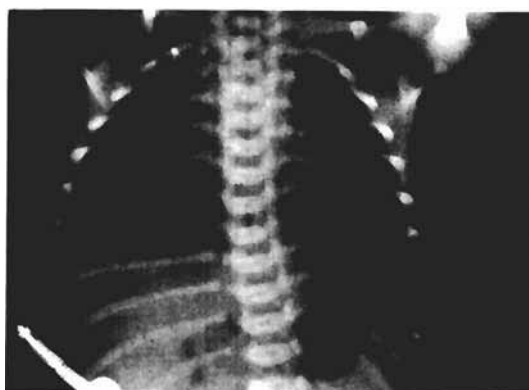

FIG. 2. A stillframe from a two-dimensional echocardiogram in the apical 4 chamber view with the transducer pointing anteriorly and superiorly, demonstrating the origin of both great arteries from the right ventricle.

(Ao =aorta. PA =pulmonary artery, LPA =left pulmonary artery. RV =right ventricle. RPA =right pulmonary artery)

Clinical course: On the second day of life he presented with several hypercyanotic spells not responsive to I.V. morphine nor I.V. propranolol. He was finally stabilized on a prostaglandin (POE) drip to maintain ductal patency ensuring good pulmonary blood flow. On day 5 of life he underwent primary intraventricular tunnel repair of the DORV with resection of the infundibular and pulmonic stenosis, enlargement of the right ventricular outflow tract and main pulmonary artery with a pericardial transannular patch, repair of the LPA stenosis, PDA division, and partial closure of the secundum ASD. He was discharged home after an uneventful postoperative period on maintenance with digoxin and was doing well and gaining weight.

Discussion

Cardiac malformations are a relatively common component of Robinow Syndrome [9,31]. Of the 75 published cases, ten cases (13%), including ours, have some form of cardiac malformations. It seems that patients with Robinow Syndrome and DORV described in the literature and that other forms of congenital heart disease sharing the same embryological origin (i.e. the failure to achieve normal conotruncal rotation) like other transposition of the great arteries complexes, can be theoretically expected in patients with Robinow Syndrome [10,11]. This indicates that cardiac malformations associated with Robinow Syndrome are diverse and can be life-threatening, especially in the early neonatal period. Finally, the easily-recognizable specific phenotype is an excellent diagnostic guide to early recognition of such potentially serious congenital heart

malformations and, thus, all patients with suspected Robinow Syndrome should be referred to a Pediatric Cardiologist, preferably one who is in a tertiary pediatric center where intensive care and cardiothoracic surgery expertise is available.

References

- [1] Robinow M. The Robinow (fetal face) Syndrome, a continuing puzzle. *Clin Dysmorphol* 1993; 2: 189-198.
- [2] Teebi AS. Autosomal recessive Robinow Syndrome. *Am J Med Genet* 1990; 35: 64-68.
- [3] Atalay S, Ege B, Imamoglu A, Suskan E, Ocal B, Gumus H. Congenital heart disease and Robinow syndrome. *Clin Dysmorphol* 1993; 2(3): 208-210.
- [4] Protnoy Y. Robinow Syndrome. *CU« Pediatr* 1979; 18: 707-708.
- [5] Bain MD, Winter RM, Burn J. Robinow Syndrome without mesomelic brachymelia. A report of five cases. *J Med Genet* 1986; 23:350-354.
- [6] Butler MG, Wadlington WB. Robinow Syndrome: report of two patients and review of literature. *Clin Genet* 1987; 31(2): 77-85.
- [7] Jewett T, Hoyme HE. Fetal face, cleft palate and digital anomalies with normal stature and associated heart defects. Further delineation of the Robinow Syndrome or a distinct entity? *Proc Greenwood Genet* 1989; 8: 203-204.
- [8] Wiens SL, Strickland DK, Snifen B, Warady BA. Robinow Syndrome: report of two patients with kidney disease. *Clin Genet* 1990; 37: 481-484.
- [9] Webber SA, Wargowski DS, Chitayat D, Sander EG. Congenital heart disease and Robinow Syndrome: coincidence or additional component of the syndrome? *Am J Med Genet* 1990; 37: 519-521
- [10] Good DA, Edward JE. The spectrum of TGA with specific reference to developmental anatomy of the conus. *CIRC* 1973; 48: 406.
- [11] Anderson RH, Wilkinson JL, Arnold R, Becker AE, Lubkiewicz K. Morphogenesis of bulbo-ventricular malformations. II. Observations on malformed hearts. *Br Heart J* 1974; 36(10): 948-970.

Not mentioned in the main text:

- [4] Balci S, Ercal MD, Say B, Turner M, Orah O, Sarinaylar S. Robinow Syndrome: fourteen cases with special emphasis on dermatoglyphics and hand malformation (split hand). *Clin Dysmorphol* 1993; 2: 199-207.
- [8] Kelly TE, Benson R, Temtamy, Plotnick L, Levin S. The Robinow Syndrome with a detailed study of the phenotype. *Am J Dis Child* 1975; 129: 383-386
- [9] Pfeiffer RA, Muller H. [Complex of multiple malformations in two unrelated children (author's transl)]. *Pediatr Padol* 1971; 6(3): 262-267.

مدى الأمراض القلبية الخلقية في متلازمة روبينو

جميل العطا، مارك ياكيت* و أحمد الطيبي**

*شعبة أمراض قلب الأطفال، و**شعبة الوراثة الطبية، مستشفى منتريال للأطفال،

منتريال، كيويك، كندا

المستخلص . متلازمة روبينو تعتبر متلازمة وراثية نادرة وهي تجمع بين مظهر الوجه الجنيني وضمور الأعضاء التناسلية مع قصر في الأطراف Ji عدمه ، وهذه المتلازمة توجد على الضرب الوراثي السائد أو المتنحي (روبينو ١٩٩٣). هذا وقد سبق وصف الأمراض القلبية الخلقية في هذه المتلازمة، ولكن لم يسبق أن وصفت طبيعة هذه الأمراض أو وجود عامل مشترك بينها أم لا . نحن نصف حالة من حالات متلازمة روبينو والتي سُخِّصَ فيها "رض قلب خلقي معقد مكون من بطين أيمن ثنائي المخرج، ثقب تحت أورطي في الحاجز بين البطينين، ضيق في الصمام الرئوي مع ضيق أسفل هذا الصمام ووجود وصلة شريانين بين الشريان الأبهر والشريان الرئوي، كما نقدم مراجعة لكل حالات متلازمة روبينو المنشورة والتي جاء فيها وصف مرض قلبي خلقي ، وأخيراً نستنتج أن أغلب حالات متلازمة روبينو والتي حدثت معها وجود مرض قلبي خلقي، أن هذه الأمراض القلبية الخلقية تميزت بشيوع وجود إنسداد أو ضيق في مخرج البطين الأيمن، كما أن وجود البطين الأيمن ذا المخرجين في حالتنا ينبىء أن احتمال وقوع أمراض قلبية خلقية أكثر تعقيداً في هذه المتلازمة كبير وقد تشمل انقلابات الشريان الأبهر والشريبات الرئوي المعقدة . لذا نحن نوصي بأن يحظى مرضى هذه المتلازمة عند ولادتهم بعناية طبية تشمل الفحص من أجل إكتشاف الأمراض القلبية الخلقية .