

## Tachycardia: A Presenting Feature of Wernicke's Encephalopathy

T.H. ZAWAWI<sup>[1]</sup> MD, FRCP (I), K.L. MARZOUKI<sup>[1]</sup> Facharzt,  
A.G. KRISHNA<sup>[2]</sup> FRCP (Edin) DCH (London), A. MARZOUKI<sup>[3]</sup> FRCS (Canada),  
Z. ABUNIJEM<sup>[2]</sup> MB, ChB and M. BAKHARI<sup>[2]</sup> MB, ChB  
<sup>[1]</sup>*Department of Medicine, <sup>[3]</sup>Department of Ophthalmology,*  
*King Abdulaziz University Hospital, Jeddah, Saudi Arabia*  
<sup>[2]</sup>*Department of Medicine, National Guard,*  
*King Khalid Hospital, Jeddah, Saudi Arabia*

**ABSTRACT.** Tachycardia as a presenting symptom and part of Wernicke's encephalopathy was detected in a patient who was having a discharging fistula from the small bowel for which he received total parenteral nutrition for approximately five weeks. Thiamine deficiency is known to occur during total parenteral nutrition and this case report describes the evolution of the cardiac and neurological manifestations of this disorder.

**KEY WORDS:** Wernicke's encephalopathy, intestinal fistula, thiamine deficiency, parenteral nutrition, sinus tachycardia, diplopia, ophthalmoplegia.

### Introduction

Wernicke's disease is a neurological disorder characterised by the triad of confusional state, abnormalities of the ocular movements and ataxia due to a deficiency of thiamine, a water soluble B complex vitamin. Besides alcoholics, it also occurs in the nonalcoholic individuals and quite often the diagnosis is delayed or missed during life. In a retrospective analysis of 131 cases who had necropsy, 80% of the patients were not diagnosed during life as harboring this condition and the final diagnosis was made possible by histological examination of the material obtained on post mortem<sup>[1]</sup>.

---

*Correspondence Address:* Dr. T.H. Zawawi, King Abdulaziz University Hospital, P.O. Box 6615, Jeddah 21452, Saudi Arabia.

Patients on enteral or parenteral feeding over a prolonged period are known to suffer from thiamine deficiency. Such situations are not common and review of the literature suggested three reports of Wernicke's encephalopathy developing in patients on prolonged feeding<sup>[2,3]</sup> and two cases following parenteral nutrition<sup>[4,5]</sup>.

The following is a description of a patient who developed cardiac and neurological manifestations of Wernicke's disease and was maintained on prolonged total parenteral nutrition for a fistula arising from the intestines.

### Case Report

A 34-year old man was admitted to the hospital because of a post appendectomy abscess. The patient was taken to theatre for incision and drainage. Post-operatively, he had a small bowel fistula at the appendectomy site. This drained 2 to 3 litres per day.

The patient was kept nil per oral and was started on total parenteral nutrition (nitrogen 9.4 g/l; carbohydrate 40 g; lipid 135 g; electrolytes, trace elements, and fat soluble vitamins. Thiamine was not supplemented regularly.

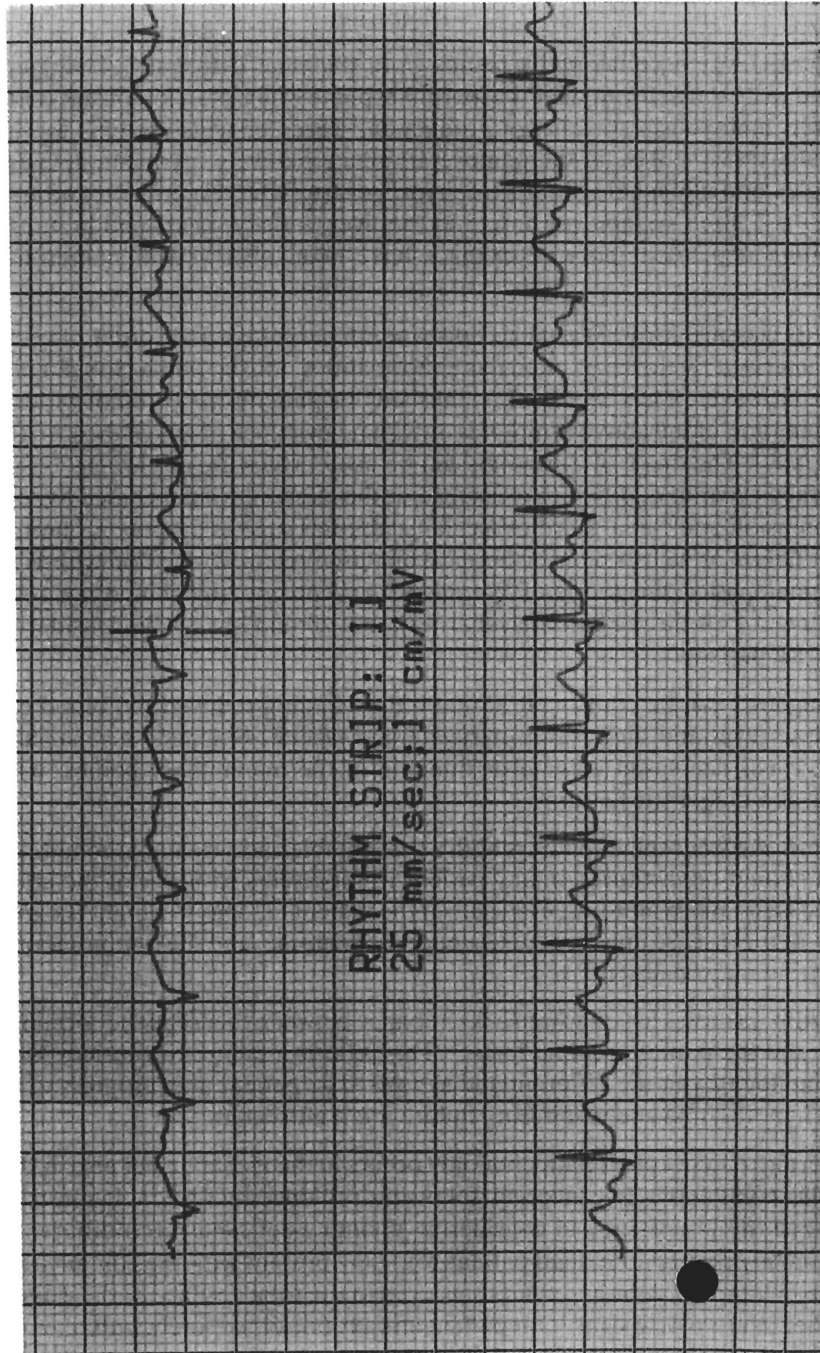
Five weeks after admission and surgical care, a medical consultation was requested because of the detection of sinus tachycardia with the heart rate at 140 per minute. The patient was emaciated but remained alert and fully oriented. He had a discharging fistula in the right iliac fossa. The rest of the physical examination was normal and the patient did not have any evidence of cardiomegaly.

Laboratory investigation showed normal blood counts and biochemical parameters. An electrocardiogram revealed the presence of sinus tachycardia at 140 per minute (Fig. 1). X-ray of the chest did not reveal enlargement of the heart. Abdominal ultrasound did not reveal any evidence of hepatosplenomegaly. Lung perfusion scan was reported to be within normal limits.

On the second day TPB was discontinued, and the patient was given 5% dextrose instead. Later in the day he complained of deterioration of his visual acuity and diplopia. He had ataxic gait but was conscious and well oriented. Examination of the eyes showed bilateral ptosis, horizontal nystagmus with some vertical component, internuclear ophthalmoplegia, complete paralysis of the right VI cranial nerve with partial paralysis of the left VI nerve.

The patient was given 250 mg thiamine intravenously daily for one week. Ophthalmological assessment confirmed the presence of limitation of the ocular movements, nystagmus and bilateral visual field defects involving the upper temporal fields with centrocaecal scotoma. A CT examination of the head did not reveal neurological lesions or oedema of the brain.

During the next two days, all neurological signs gradually disappeared apart from nystagmus which persisted. Two weeks later the patient underwent corrective surgery and at the time of discharge all symptoms and signs had completely abated.



### Discussion

Wernicke's encephalopathy results from thiamine deficiency. Thiamine is converted to its active form, thiamine pyrophosphate which is an important coenzyme in glucose metabolism for energy production. Three enzyme systems are involved, namely, transketolase in the pentosephosphate pathway, pyruvate dehydrogenase complex and alpha ketoglutarate dehydrogenase (KGDH) in the tricarboxylic acid cycle. All three systems are found in the liver, kidney, heart and brain. Cerebral thiamine dependent enzyme changes have been observed in numerous animal studies<sup>[6]</sup>.

In its classical form, Wernicke's disease is a neurological disorder of acute onset, characterised by the triad of ocular abnormalities, ataxia, and a global, confusional state. However, it has been well established that patients may present with a variable combination of the above symptoms or with no evidence of any of those in the classical triad<sup>[7]</sup>. The onset of symptoms can be acute, subacute or chronic<sup>[8]</sup>. Symptoms that may occur in addition to or instead of the classical triad included hypothermia, hypotension and coma. Cardiovascular symptoms such as dyspnoea, chest pain and heart failure as well as neuritic beriberi are also seen in association with Wernicke's encephalopathy. Diagnosis of Wernicke's encephalopathy should not rely on the presence of all three neurological criteria but should always be considered in any high risk patient<sup>[9]</sup>.

Diagnosis can be confirmed during life by finding reduced red blood cell transketolase level and high serum pyruvate and lactate. Magnetic resonance imaging may reveal decreased volume or thinning of the mammillary bodies, which may prove as a diagnostic feature<sup>[10]</sup>.

Wernicke's encephalopathy is both a preventable and a treatable condition. Treatment should be instituted in any patient who presents with any of the above mentioned signs and symptoms, especially if the patient belongs to a high risk group. The onset of the disease may be acute, subacute or chronic, and the symptoms of the classical triad may be absent<sup>[8]</sup>.

Autopsy studies have showed a discrepancy between the frequency of clinical diagnosis and the pathological findings<sup>[9]</sup>. This reflects a failure to consider Wernicke's encephalopathy in the differential diagnosis. The patient may progress to hypotension, hypothermia and respiratory failure if left untreated.

Wernicke's encephalopathy not only occurs in the alcoholic but also in the nonalcoholic population. It can occur following prolonged TPN<sup>[4,5]</sup>. It must be reemphasized the importance of considering thiamine deficiency as a differential diagnosis in any poorly nourished patient who may present with the combination of the above mentioned signs and symptoms even in the total absence of the classical triad or other neurological signs. Our patient initially presented solely with sinus tachycardia, which was not reported before and it stresses the varied symptomatology of Wernicke's encephalopathy.

TABLE 1. Causes of Wernicke's encephalopathy.

Alcoholism
Nonalcoholism:
Total parenteral nutrition
Enteral feeding
Hyperemesis gravidarum
Anorexia nervosa
Prolonged fasting
Carbohydrate overload after starvation
Following lithium induced diarrhoea <sup>[11]</sup>
Gastric plication for morbid obesity <sup>[11]</sup>
Thyrototoxicosis
Peritoneal or haemodialysis <sup>[13]</sup>

### References

- [1] **Christian FL.** Wernicke's encephalopathy in nonalcoholics. An autopsy study. *J Neurol Sci* 1989; **90**: 125-9.
- [2] **Seear MD.** Two cases of Wernicke's encephalopathy in children: An under diagnosed complication of poor nutrition. *Ann Neurol* 1988; **24**: 85-7.
- [3] **Blennow G.** Wernicke's encephalopathy following prolonged artificial nutrition. *Am J Dis Child* 1975; **129**, 12, p. 1456.
- [4] **Mayer's C et al.** Wernicke's encephalopathy in infancy: development during parenteral nutrition. *Acta Neuropatho (Berl)* 1978; **43**: 267-9.
- [5] **Mattioli S, Miglioli M, Montagna P, Lerro MF, Pilotti V, Gozetti G.** Wernicke's encephalopathy during total parenteral nutrition: observation in one case. *J Parent Ent Nutr* 1988; **12**: 626-7.
- [6] **Butterworth RF.** Cerebral thiamine-dependent enzyme changes in experimental Wernicke's encephalopathy. *Metabol Brain Dis* 1986; **1**: 165-175.
- [7] **Harper GC.** Clinical signs in the Wernicke-Korsakoff complex: a retrospective analysis of 131 cases diagnosed at necropsy. *J Neurol Neurosurg Psychiatry* 1986; **49**: 341-5.
- [8] **Naidoo DP.** Wernicke's encephalopathy in Durban: a retrospective analysis. *S Afr Med J* 1988; **74**: 293-4.
- [9] **Brew BJ.** Diagnosis of Wernicke's encephalopathy. *Aust Nz J Med* 1986; **16**: 6768.
- [10] **Charness ME.** Mammillary body atrophy in Wernicke's encephalopathy: antemortem identification using magnetic resonance imaging. *Ann Neurol* 1987; **22**: 595-600.
- [11] **Epstein RS.** Wernicke's encephalopathy following lithium induced diarrhoea. *Am J Psychiatry* 1989; **146**: 806-7.
- [12] **Kramer LD.** Wernicke's encephalopathy. Complication of gastric plication. *J Clin Gastroenterol* 1987; **9**: 549-552.
- [13] **Jagadha V.** Wernicke's encephalopathy in patients on peritoneal dialysis or haemodialysis. *Ann Neurol* 1987; **21**: 78-84.

## تسارع ضربات القلب أحد أعراض التهاب المخ (فيرنكس)

طريف الزواوي<sup>(١)</sup> خالد مرزوقي<sup>(١)</sup> أ. ج. كريشنا<sup>(٢)</sup>  
عدنان مرزوقي<sup>(٣)</sup> زهير أبو نجم<sup>(٢)</sup> ملك بخاري<sup>(٢)</sup>  
<sup>(١)</sup>، <sup>(٣)</sup> مستشفى جامعة الملك عبد العزيز ، <sup>(١)</sup> مستشفى الملك خالد للحرس الوطني  
جدة - المملكة العربية السعودية

المستخلص . إن تسارع ضربات القلب بصفته أحد الأعراض المصاحبة لالتهاب المخ النصفى (فيرنكس) كان قد تم اكتشافه في أحد المرضى المصابين بناصر الأمعاء الدقيقة والذي ظل يغذى تغذية صناعية لفترة خمسة أسابيع تقريباً .

كما تعرض هذا المريض لنقص فيتامين (ب<sub>١</sub>) كنتيجة طبيعية لاعتقاده كلياً على التغذية الصناعية . ويوضح التقرير الطبي لهذه الحالة الظواهر القلبية والعصبية المصاحبة لذلك .